

## Central Lancashire Online Knowledge (CLOK)

Title	ERS International Congress 2023: highlights from the Clinical Techniques, Imaging and Endoscopy Assembly.
Type	Article
URL	<a href="https://clock.uclan.ac.uk/50852/">https://clock.uclan.ac.uk/50852/</a>
DOI	<a href="https://doi.org/10.1183/23120541.00836-2023">https://doi.org/10.1183/23120541.00836-2023</a>
Date	2024
Citation	Moretti, Antonio, Pietersen, Pia Iben, Hassan, Maged, Shafiek, Hanaa, Prosch, Helmut, Tarnoki, Adam Domonkos, Annema, Jouke T, Munavvar, Mohammed, Bonta, Peter I et al (2024) ERS International Congress 2023: highlights from the Clinical Techniques, Imaging and Endoscopy Assembly. ERJ Open Research, 10 (1).
Creators	Moretti, Antonio, Pietersen, Pia Iben, Hassan, Maged, Shafiek, Hanaa, Prosch, Helmut, Tarnoki, Adam Domonkos, Annema, Jouke T, Munavvar, Mohammed, Bonta, Peter I, de Wever, Walter and Juul, Amanda Dandanell

It is advisable to refer to the publisher's version if you intend to cite from the work.  
<https://doi.org/10.1183/23120541.00836-2023>

For information about Research at UCLan please go to <http://www.uclan.ac.uk/research/>

All outputs in CLOK are protected by Intellectual Property Rights law, including Copyright law. Copyright, IPR and Moral Rights for the works on this site are retained by the individual authors and/or other copyright owners. Terms and conditions for use of this material are defined in the <http://clock.uclan.ac.uk/policies/>



# ERS International Congress 2023: highlights from the Clinical Techniques, Imaging and Endoscopy Assembly

Antonio Moretti <sup>1,2</sup>, Pia Iben Pietersen <sup>3,4</sup>, Maged Hassan <sup>5</sup>, Hanaa Shafiek <sup>5</sup>, Helmut Prosch <sup>6</sup>, Adam Domonkos Tarnoki<sup>7,8</sup>, Jouke T. Annema<sup>1</sup>, Mohammed Munavvar<sup>9</sup>, Peter I. Bonta<sup>1</sup>, Walter de Wever<sup>10</sup> and Amanda Dandanell Juul <sup>11,12</sup>

<sup>1</sup>Department of Pulmonology, Amsterdam University Medical Centres, Amsterdam, The Netherlands. <sup>2</sup>Unit of Respiratory Diseases, Department of Medical and Surgical Sciences, University Hospital of Modena, University of Modena and Reggio Emilia, Modena, Italy. <sup>3</sup>Department of Radiology, Odense University Hospital Svendborg, Svendborg, Denmark. <sup>4</sup>Research and Innovations Unit of Radiology, University of Southern Denmark, Odense, Denmark. <sup>5</sup>Chest Diseases Department, Alexandria University Faculty of Medicine, Alexandria, Egypt. <sup>6</sup>Department of Biomedical Imaging and Image-guided Therapy, Medical University of Vienna, Vienna, Austria. <sup>7</sup>Medical Imaging Centre, Semmelweis University, Budapest, Hungary. <sup>8</sup>National Tumour Biology Laboratory, Oncologic Imaging and Invasive Diagnostic Centre, National Institute of Oncology, Budapest, Hungary. <sup>9</sup>Lancashire Teaching Hospitals and University of Central Lancashire, Preston, UK. <sup>10</sup>Department of Radiology, University Hospitals Leuven, Leuven, Belgium. <sup>11</sup>Odense Respiratory Research Unit (ODIN), Department of Clinical Research, University of Southern Denmark, Odense, Denmark. <sup>12</sup>Department of Respiratory Medicine, Odense University Hospital, Odense, Denmark.

Corresponding author: Amanda Dandanell Juul ([Amanda.Dandanell.Juul@rsyd.dk](mailto:Amanda.Dandanell.Juul@rsyd.dk))



Shareable abstract (@ERSpublications)

#ERSCongress 2023 included new studies in the fields of interventional pulmonology, imaging and ultrasound in several disease categories such as lung cancer, obstructive lung disease and interstitial lung disease <https://bit.ly/3MD7O98>

Cite this article as: Moretti A, Pietersen PI, Hassan M, et al. ERS International Congress 2023: highlights from the Clinical Techniques, Imaging and Endoscopy Assembly. *ERJ Open Res* 2024; 10: 00836-2023 [DOI: 10.1183/23120541.00836-2023].

Copyright ©The authors 2024

This version is distributed under the terms of the Creative Commons Attribution Non-Commercial Licence 4.0. For commercial reproduction rights and permissions contact [permissions@ersnet.org](mailto:permissions@ersnet.org)

Received: 1 Nov 2023  
Accepted: 2 Nov 2023

## Abstract

The Clinical Techniques, Imaging and Endoscopy Assembly is involved in the diagnosis and treatment of several pulmonary diseases, as demonstrated at the 2023 European Respiratory Society (ERS) International Congress in Milan, Italy.

From interventional pulmonology, the congress included several exciting results for the use of bronchoscopy in lung cancer, including augmented fluoroscopy, robotic-assisted bronchoscopy and cryobiopsies. In obstructive lung disease, the latest results on bronchoscopic treatment of emphysema with hyperinflation and chronic bronchitis were presented. Research on using cryobiopsies to diagnose interstitial lung disease was further explored, with the aims of elevating diagnostic yield and minimising risk.

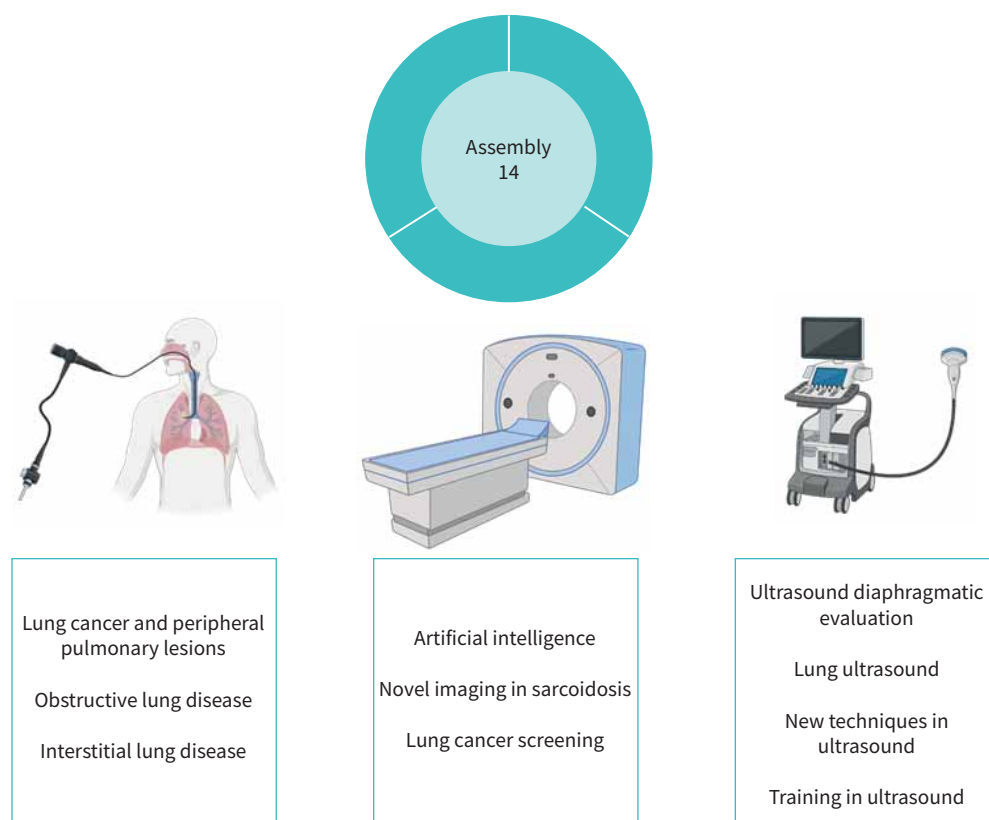
For imaging, the latest updates in using artificial intelligence to overcome the increased workload of radiologists were of great interest. Novel imaging in sarcoidosis explored the use of magnetic resonance imaging, photon-counting computed tomography and positron emission tomography/computed tomography in the diagnostic work-up. Lung cancer screening is still a hot topic and new results were presented regarding incorporation of biomarkers, identifying knowledge gaps and improving screening programmes.

The use of ultrasound in respiratory medicine is an expanding field, which was demonstrated by the large variety in studies presented at the 2023 ERS Congress. Ultrasound of the diaphragm in patients with amyotrophic lateral sclerosis and myasthenia gravis was used to assess movements and predict respiratory fatigue. Furthermore, studies using ultrasound to diagnose or monitor pulmonary disease were presented. The congress also included studies regarding the training and assessment of competencies as an important part of implementing ultrasound in clinical practice.

## Introduction

The European Respiratory Society (ERS) International Congress 2023 was hosted in Milan, offering both onsite participation and online attendance. A myriad of sessions and presentations demonstrated the recent advances in the field of respiratory medicine, with exciting new results. Assembly 14 was responsible for 181 accepted abstracts, and the fields of interventional pulmonology, imaging and ultrasound played an





**FIGURE 1** Overview of the groups and topics covered by the Clinical Techniques, Imaging and Endoscopy Assembly (Assembly 14). From left to right: group 14.01 Interventional pulmonology; group 14.02 Imaging; group 14.03 Ultrasound.

important part in sessions from the other assemblies (figure 1). In this article, early-career members and leaders of the assembly present their highlights from the ERS Congress 2023.

#### Group 14.01: Interventional pulmonology

##### *Lung cancer and peripheral pulmonary lesions*

Diagnosis of peripheral pulmonary nodules (PPNs) remains one of the biggest challenges in interventional pulmonology. As lung cancer screening programmes using low-dose chest computed tomography (CT) are being implemented in several countries worldwide, PPN detection is expected to rise considerably. Slim bronchoscopes and navigation strategies (including electromagnetic and virtual navigation bronchoscopy, cone-beam CT and robotic-assisted bronchoscopy (RAB)) enable the bronchoscopist to reach and diagnose small peripheral lung lesions that previously would have seemed out of reach. However, diagnostic yield can be optimised, and tool-in-lesion (TIL) imaging confirmation remains a challenge [1]. There is growing evidence that intra-procedural advanced imaging is key to bridge the gap [2, 3].

Novel potential solutions to overcome these challenges were presented at the endoscopy session titled “Cutting-edge concepts for diagnosis of peripheral lesions: the future is here!” First, an augmented three-dimensional (3D)-fluoroscopy imaging platform, LungVision (Body Vision Medical Inc.), was demonstrated, which enables integration of two-dimensional X-ray images obtained by C-arm with CT scans and virtual navigation systems.

In the same session, trial results on RAB nodule detection were presented. BROCK *et al.* [4] carried out a prospective single-centre, single-arm trial that included 41 patients with a single PPN sized <30 mm, who underwent nodule detection using RAB, radial endobronchial ultrasound (rEBUS) and cone-beam CT. The primary outcomes were TIL confirmation rate, safety and diagnostic yield. No severe adverse events, no pneumothorax and one airway bleeding were reported. TIL rate was 100% and diagnostic yield was 91.4%, with a mean procedure time of 44 min.

Needle-based confocal laser endomicroscopy (nCLE) is also considered a promising technology for TIL confirmation. An advantage proposed for nCLE is that TIL is further refined by needle-based imaging at the tip of the needle (needle-in-target). Alongside previous reports on PPN, KRAMER and co-workers [5, 6] presented an observational study on nCLE, evaluating its performance in the diagnosis of granulomatous diseases.

Further highlighting the efforts across the globe to overcome the clinical challenges of PPN diagnosis, two other studies were presented. FURUSE *et al.* [7] evaluated the diagnostic efficacy of cryobiopsies for PPN while LEE-MATEUS *et al.* [8] combined RAB with 3D-fluoroscopy. In the former study, 481 patients who underwent cryobiopsies of PPNs were matched for baseline characteristics with 481 patients who underwent transbronchial biopsies. Virtual bronchoscopy and rEBUS were used in all patients. The diagnostic yield was significantly higher in the cryobiopsy group than in the conventional group (89.2% versus 77.6%; OR 2.36, 95% CI 1.65–3.38). Grade 2/3 bleeding occurred more frequently in the cryobiopsy group than in the conventional group (grade 2: 38.0% versus 10.2%; grade 3: 1.5% versus 0.8%;  $p < 0.001$ ); no grade 4 bleeding was observed. Comparable results were found by NAKAI *et al.* [9], who presented a single-centre retrospective study evaluating the diagnostic utility and safety of 1.1-mm probe cryobiopsies in non-intubated patients with PPN suspicious/suspected for lung cancer, added to conventional biopsy techniques under rEBUS and virtual bronchoscopy guidance. They included 113 patients in the final analysis. The diagnostic yields of conventional biopsy and cryobiopsy were 70.8% and 82.3%, respectively ( $p = 0.009$ ). The total diagnostic yield was 85.8%, significantly higher than by conventional forceps biopsy alone. Severe complications were not observed, and only one moderate bleed occurred.

When reaching and TIL confirmation of a peripheral tumour is secured, ablative endoscopic treatment is on the horizon. K. Lau (London, UK) reported on the 5-year experience of St Bartholomew's Hospital (London) in microwave PPN ablation. Navigation bronchoscopy, a flexible microwave ablation catheter and cone-beam CT were used in all 80 patients, and 107 nodules were ablated, of which 65% were oligo-metastases. The rate of grade 3 and higher complications was 8.4%, including one death. Overall recurrence rate at 747 days of follow-up was 18%.

A different ablative technique is radiofrequency ablation. ZHONG *et al.* [10] presented the preliminary results of their multicentre, prospective, single-arm study that included 126 patients (NCT04619472). Within this trial, transbronchial radiofrequency ablation treatment for peripheral lung tumours resulted in a complete ablation rate of 92.1% (116 out of 126) and 82.9% (63 out of 76) at 6 and 12 months, respectively. Grade 3 or above adverse events related to ablation occurred in 41 out of 148 (28%), of which pulmonary inflammation (24 out of 41), pulmonary infection (five out of 41), pneumothorax (three out of 41), chest pain (two out of 41), pleural effusion (one out of 41) and haemoptysis (one out of 41) were reported.

### Obstructive lung diseases

In interventional pulmonology, over the years several efforts have been undertaken to develop and evaluate treatment modalities for obstructive airways diseases. These include endoscopic lung volume reduction (ELVR) for emphysema with hyperinflation, targeted lung denervation for COPD, rheoplasty and cryospray for chronic bronchitis and bronchial thermoplasty for asthma.

The ERS Congress 2023 hosted a highly educational and inspiring speaker session focused on innovative treatments in interventional pulmonology that highlighted these topics: “Innovative interventions in pulmonology: freeze, fry or fume?”

### Chronic bronchitis

A comprehensive lecture on bronchial rheoplasty for chronic bronchitis, including the mechanism of action and procedural details, was given by K. Kontogianni (Heidelberg, Germany). Five clinical trials have been initiated to assess the safety and effectiveness of rheoplasty. Of those, one is complete and published [11], while the remaining four are still ongoing and have completed the enrolment phase. Novel data about bronchial rheoplasty from the European Registry Study were presented by BROCK *et al.* [12]. The RheOx Registry Study was conducted on 50 patients in eight centres. Outcomes after 6 months were safety and symptoms burden, investigated by validated questionnaires (St George's Respiratory Questionnaire (SGRQ) and COPD Assessment Test (CAT)). In total, 41 patients underwent a 6-month follow-up after the two bronchial rheoplasty sessions. At baseline, participants had a mean  $\pm$  SD age of 67.2  $\pm$  8.7 years, forced expiratory volume in 1 s (FEV<sub>1</sub>) of 58.9  $\pm$  25.9% predicted, SGRQ score of 54.8  $\pm$  18.2 and CAT score of 24.9  $\pm$  7.0. In terms of severe adverse events, 16 were reported in 10 patients, of which 10 occurred in the

first 30 days, mainly COPD exacerbations. At 6 months, 73% of patients reached or exceeded the minimal clinically important difference for CAT and 63% for SGRQ. At baseline, CAT responders ( $n=30$ ) had significantly less residual volume (RV) (153.6% *versus* 197.3%), higher FEV<sub>1</sub> (64.0% *versus* 39.0%) and higher 6-min walk test (6MWT) distance (401.6 m *versus* 273.1 m) than non-responders.

Another recent innovation in bronchoscopic treatment for chronic bronchitis is metered cryospray. ORTON *et al.* [13] presented their observational study on patient-reported outcomes at 6-month follow-up, relative to baseline, in 15 patients. SGRQ and CAT scores significantly improved.

### *Emphysema and hyperinflation*

For ELVR treatment, most evidence is available for endobronchial valve (EBV) implant, which has been adopted by the 2023 Global Initiative for Chronic Obstructive Lung Disease (GOLD) COPD guidelines. Collateral ventilation (CV) is one of the main exclusion criteria for ELVR with EBV. In recent years AeriSeal foam has shown proof of principle to convert CV<sup>+</sup> patients into CV<sup>-</sup> patients. The CONVERT trial (NCT04559464) has stopped enrolment at 102 patients and an interim analysis of the data was presented by M. Bezzi (Brescia, Italy). This prospective, multicentre, open label, single-arm trial recruited subjects eligible for EBV treatment except for CV<sup>+</sup> status with at least 80% of target fissure completeness. After the sealing treatment, CV status was assessed by the Chartis system 6 weeks later and, in case of CV conversion, ELVR-EBV was performed. Only one sealing retreatment was possible in case of failure. Currently, outcome data are available for 40 patients and show that a CV<sup>+</sup> status conversion was achieved in 71% of patients, while the mean target lobe volume reduction was 1107±662 mL. Adverse events occurred in 16 patients, eight of whom experienced a post-acute inflammatory reaction and were treated with pharmacological therapy to full recovery. Final results are expected to be available by 2024.

An interesting multicentre, randomised, non-blinded clinical trial analysing the impact and timing of pulmonary rehabilitation (PR) in patients undergoing ELVR-EBV was also presented [14]. In this trial, 97 subjects were randomised into three groups: PR before ELVR-EBV, PR after ELVR-EBV and ELVR-EBV without PR. The primary outcome was the change in constant work rate cycle test (CWRCT) endurance time at 6-month follow-up between the PR groups and ELVR-EBV-only group. Secondary end-points included changes in 6MWT, daily step count and patient-reported outcomes. At 6-month follow-up, there was no difference in change in CWRCT endurance time or in any of the secondary end-points between the PR groups and ELVR-EBV-only group. Similarly, no differences were measured in change in CWRCT endurance time or in the secondary end-points between the groups that underwent PR before and after ELVR-EBV.

Emphysema heterogeneity might play a role in clinical outcomes after EBV treatment, and this was analysed by Roodenburg *et al.* [15] using the BREATH-NL registry. A heterogeneous distribution was related to larger improvement, but a more homogeneous emphysema distribution also resulted in significant improvements.

With an elegant retrospective study, Schuler *et al.* [16] analysed the response prediction for ELVR-EBV in 167 COPD patients. They found that the baseline deflation volume of the target lobe at expiration (to measure FEV<sub>1</sub>), obtained by multi-detector CT, is a predictor of clinical outcome following treatment.

As well as EBVs, intrabronchial valves are also available. Dittrich *et al.* [17] analysed ELVR treatment combining both valve types. Their retrospective analysis included 89 patients with severe heterogeneous emphysema and intrabronchial valves were mostly implanted in the lower lobes. At 90-day follow-up, lobar atelectasis occurred in 53% of cases, with significant improvement in FEV<sub>1</sub>, RV, 6MWT and modified Medical Research Council dyspnoea score. The rate of adverse events was comparable to that reported in the literature.

Bronchoscopic thermal vapor ablation (BTVA) is another emerging option for lung volume reduction in patients with severe upper lobe-predominant emphysema. Kontogianni *et al.* [18] shared their results from an ongoing prospective registry after 36 months of follow-up. FEV<sub>1</sub>, RV, 6MWT and SGRQ measurements were analysed prior to treatment and at follow-up for 204 patients. In total, 116 subjects were followed up for 12 months, 63 for 24 months and 42 for 36 months, for a total of 314 BTVA procedures. There were 97 procedure-related serious adverse events reported. SGRQ and RV significantly improved at 12 months and SGRQ at 24 months. Changes in FEV<sub>1</sub> and 6MWT did not achieve statistical significance. Limited by low numbers, at 36-month follow-up, none of the measurements achieved a statistically significant difference from baseline.

### Interstitial lung diseases

Current guidelines recommend transbronchial lung cryobiopsy (TBLC) as a less invasive alternative to surgical lung biopsy to obtain biopsies for patients affected by undiagnosed interstitial lung diseases (ILDs) who are eligible for surgery and for those who are not [19].

Technological advancement expands the range of tools available for clinical practice to reach this goal, and one of these is the 1.1-mm cryoprobe applied to TBLC studies in ILD. Hou *et al.* [20] presented their randomised controlled trial comparing the 1.1-mm and the 1.9-mm probes for cryobiopsies in patients with undiagnosed ILDs. They randomly allocated 224 patients 1:1 in the two groups. The average biopsy sample surface area was  $20.2 \pm 7.9 \text{ mm}^2$  in the 1.9-mm probe group and  $16.3 \pm 14.3 \text{ mm}^2$  in the 1.1-mm probe group ( $p=0.019$ ). While there were no significant differences in diagnostic yield (80.4% versus 79.8%) and sample quality, moderate bleeding was significantly more frequent in the 1.9-mm probe group (17% versus 6.2%). More pneumothorax cases occurred in the 1.1-mm probe group (7.1% versus 1.8%), although this difference was not statistically significant.

Freund *et al.* [21] presented an observational multicentre study that compared TBLC and transbronchial lung forceps biopsy (TBFB) in 276 patients with both fibrotic and nonfibrotic undiagnosed ILDs. In total, 160 subjects underwent TBFB and 116 underwent TBLC. Fibrotic ILDs were present in 148 patients (54%). Diagnostic yield was 78% and 48% for TBLC and TBFB, respectively (adjusted OR 4.2, 95% CI 2.4–7.6,  $p<0.01$ ). The diagnostic yield of TBLC was higher than TBFB among patients with fibrotic ILD, nonfibrotic ILD and across most ILD diagnoses. TBLC was associated with a higher risk for significant bleeding (10% versus 3%), but the risk for pneumothorax was similar between the two groups.

Another novel development in this field is the potential for imaging techniques to overcome the need for histopathological biopsy. Soldati *et al.* [22] presented a proof-of-principle study on endobronchial polarisation-sensitive optical coherence tomography (EB-PS-OCT). This is a feasible, safe and minimally invasive imaging technique to detect ILD hallmarks, including microcystic honeycombing, and quantify pulmonary fibrosis. As such, EB-PS-OCT is a promising technique that could be used as an add-on bronchoscopic imaging technique to characterise and assess (progressive) fibrosis in ILD patients.

### Group 14.02: Imaging

#### Artificial intelligence

In the 2023 ERS Congress, a dedicated session on artificial intelligence (AI) in thoracic imaging was held. R. Vliegthart (Groningen, the Netherlands) initiated the session by polling the audience about their current AI experience. The answers likely mirrored those of ERS members; 33% had only limited experience and knowledge with AI, 25% used AI without familiarity with the AI technique, 33% used and understood AI in clinical practice, and 7% were professional AI developers. It is evident that a considerable number of ERS Congress attendees are already integrating AI into their clinical routines. AI in radiology or imaging creation is an overarching term that describes the use of machine-learning algorithms applied in various processes, from image manufacturing to image reconstruction to assessment of the final images. The session covered several AI topics, summarised below.

Currently, the most recent published literature predominantly focuses on early lung cancer detection or on detection, classification and segmentation of lung nodules. This emphasis stems from increased chest CT usage leading to more incidental findings and the impending launch of lung cancer screening programmes worldwide [23, 24]. The workload of thoracic radiologists is anticipated to rise and AI could potentially be one of the solutions to manage this. Recent systematic reviews endorse AI assistance in lung nodule detection, exhibiting accuracy ranging from 82% to 98% and surpassing radiologists by 7% to 56%, particularly in detecting small nodules and among younger radiologists. AI has also contributed to reducing false-positive rates within recent years [25–27].

Depending on the application point, AI could both decrease reading time by 11–30% in concurrent mode or increase it when used as a second reader. At the present time, it is not legal to use AI as first reader. The National Institute for Health and Care Excellence has reported limited evidence on AI cost-effectiveness in nodule detection but AI appears to be more valuable and efficient in the setting of lung cancer screening [28]. While sparse evidence has been published on nodule classification [29], AI solutions for risk assessment have been explored, revealing high agreement between radiologists and AI. However, in many cases with discrepancies, AI has often demonstrated better performance [30]. The newest publications suggest AI models for risk assessment algorithms, *e.g.* using a baseline thoracic CT scan, can predict 6-year cancer risk [31]. During the same session, N. Sverzellati (Parma, Italy) presented



the newest AI for lung fibrosis and M. De Bruijne (Rotterdam, the Netherlands) presented AI in organ segmentation, *e.g.* for quantifying emphysema and pulmonary artery/aorta ratio.

AI has potential in multiple facets of the imaging process. First, AI can enhance images through pre-processing and reconstruction, thereby reducing radiation exposure. Second, AI can reduce and prioritise the radiologists' workload, *e.g.* using post-processing detection, segmentation or sizing of lung nodules or creating an urgency list on which scans need to be reported faster. Third, AI can increase accuracy and decrease interrater variability. R. Vliegenthart also highlighted the challenges that need to be overcome before AI implementation in thoracic imaging, including data governance; algorithm robustness across scanner, patient or organ variation; data label quality; and stakeholder consensus. Most studies and published evidence describe the development and/or the internal validation of the AI algorithm, but there is a lack of evidence on external validation, *e.g.* comparison of AI classification and lung nodule biopsy results.

### *Novel imaging in sarcoidosis*

Sarcoidosis is a systemic disease of unknown aetiology characterised by granulomatous inflammation in various organ systems and very often includes pulmonary manifestation. An important challenge is that a definitive diagnostic test does not exist and establishing a diagnosis often relies on compatible clinical and radiographic presentations and exclusion of other diseases, benign or malignant. In the session "The role of novel imaging modalities in sarcoidosis diagnosis and management", photon-counting CT (PCCT), magnetic resonance imaging (MRI) and positron emission tomography (PET) were explored and discussed as potential tools for diagnosing and managing sarcoidosis.

PCCT is a novel CT technique in which the CT detectors count the number of incoming photons and measure photon energy, resulting in a higher contrast-to-noise ratio, improved spatial resolution and optimised spectral imaging. Additionally, the radiation dose for PCCT is reduced compared to conventional chest CT. A.D. Tamoki (Budapest, Hungary) presented recent studies on PCCT and ILD, summarising that PCCT has decreased the radiation dose and improved imaging quality for visualising distal bronchial divisions, depicting bronchial walls and providing more precise delineation of fibrotic abnormalities. The number of publications on this topic is limited and the clinical applications are still to be explored.

Normally, MRI is used in patients suspected of cardiac sarcoidosis involvement. J.H. Chung (Chicago, IL, USA) highlighted that non-cardiac thoracic MRI for sarcoidosis is underutilised but has the potential for broader application. The practical advantages include the absence of radiation, making MRI ideal for young people, children and patients who require frequent follow-up imaging. Additionally, MRI is superior to CT in terms of soft tissue assessment and detection of localised oedema, fluid and inflammation. However, there are challenges that need to be overcome such as scan time. Protocols must not be too long owing to economic cost-benefit considerations, but also because dyspnoeic patients must be able to lie flat during the scan. J.H. Chung presented several clinical examples comparing CT and MRI scans, demonstrating MRI's ability to detect lung parenchymal changes in sarcoidosis, including perilymphatic nodules and fibrosis with reticular and ground-glass opacities. In the future, it is expected that newer strategies and research will increase the utility of MRI.

Last, Z. Besenyi (Szeged, Hungary) explained that fluorodeoxyglucose (FDG) PET/CT is able to obtain a systemic granulomatous distribution map of all lesions in patients suspected of sarcoid multiorgan involvement, but has most additional value in cardiac sarcoidosis, *e.g.* increased sensitivity for FDG-PET/CT-guided endomyocardial biopsy, for inclusion or exclusion of non-caseous granuloma in other organ systems, or for diagnosis of cardiac sarcoidosis on already extra-cardiac histological and imaging criteria. FDG-PET/CT is also an important tool in the treatment decision or monitoring of cardiac sarcoidosis, because it can distinguish between responders and non-responders as well as guiding implantable cardioverter defibrillator and/or pacemaker implementation decisions. For pulmonary sarcoidosis, FDG-PET/CT can potentially aid in assessing the response to therapy and should be considered on a case-by-case basis by a multidisciplinary team.

Diagnosis and management of sarcoidosis remains a challenge owing to the need for an overall assessment of several features. While radiological features and imaging hold promise for aiding in diagnosis and decision-making, factors such as radiation exposure and cost-effectiveness need careful consideration. Each imaging decision should be evaluated individually for specific patients.

### *Lung cancer screening*

Lung cancer screening is a hot topic, and at the ERS Congress 2023, there were sessions providing an overview of current evidence from screening trials. Other presentations and posters discussed new features and alternatives for lung cancer screening.

The availability of CT varies around the world, and while lung cancer screening and CT scans in general are feasible in western countries, other areas suffer from limited access. CASAGRANDE *et al.* [32] presented a case-control study in which they explored plasma and sputum for miRNA and identified some miRNA signatures in the liquid biopsies that could potentially guide the selection of individuals for CT screening. ZWIJSEN *et al.* [33] presented a study of breath test analysis as a noninvasive and early-stage biomarker provided as an add-on to the assessment of patients with an incidental nodular finding on lung cancer screening. They concluded that there could be a role for this in the future. We expect to see more novel alternatives and solutions in the next couple of years that potentially could aid in patient selection or as an add-on in lung cancer screening programmes, especially in developing countries or for populations with long travel distances to a radiological department.

As lung cancer screening trials have demonstrated an effect on lung cancer mortality, the focus is now also turning towards all the incidental findings that are not obviously malignant. T.G. Blum (Berlin, Germany) started his presentation with a slide stating that “it is not always malignant” and presented a revisited systematic approach to diagnosing or categorising solitary pulmonary nodules. He highlighted the radiological features suggestive of benign nodules, *i.e.* smooth border, calcification with solid density, <5 mm and doubling time of <1 month or >1 year, and gave examples of benign aetiologies of solitary pulmonary nodules, with the most frequent being infectious granuloma (80%), including atypical mycobacteria, tuberculosis and coccidiomycosis, and the second most frequent being hamartomas (10%) [34]. However, it is worth noting that what is considered common in one area may not be common in another, and the same applies to rare conditions, depending on whether we are in industrialised or developing areas. The frequency and prevalence of diseases should always be taken into account when assessing nodules independent of whether they are suspected to be benign or malignant [35], and categorisation and risk prediction models can assist in the assessment [36, 37].

M-P. Revel (Paris, France) introduced us to SOLACE (Strengthening the screening of lung cancer in Europe), a 3-year implementation project funded by the EU4Health programme and coordinated by the European Institute for Biomedical Imaging Research, a part of the European Society of Radiology [38]. The aim of the project is first to assess and explore the current status of lung cancer screening programmes in Europe and identify needs and gaps, and second to produce comprehensive guidelines and work packages (WPs) on where to focus. The SOLACE project began in April 2023 and already had several approaches to report by the time of the congress in September 2023. M-P. Revel highlighted three of eight WPs, which are focus points that are investigated and explored. The three presented WPs were all directed towards participants enrolled in ongoing screening projects. WP4 focuses on enhancing the knowledge and participation of women because women are underrepresented in most lung cancer screening programmes. For example, women only represented 16% of the participants in the NELSON study and, in many trials, the male/female data are aggregated.

WP5 focuses on hard-to-reach individuals, including ethnic minorities, socially deprived populations and populations living in geographically remote regions, by educating ambassadors to promote lung cancer screening programmes and increasing the use of mobile CT units. WP6 focuses on patients with higher risk by increasing the collaboration with local physicians and patient associations. SOLACE will provide a toolbox for setting up high-quality screening programmes, which is the most immediate way of reducing lung cancer mortality.

#### Group 14.03: Ultrasound

##### *Ultrasound diaphragmatic evaluation*

The diaphragm is effectively assessed by ultrasonography and could be valuable in predicting disease outcome. ESPINOSA *et al.* [39] assessed the diaphragmatic contraction velocity in 18 patients who presented with myasthenia gravis. They used the formula  $((v_{10}-v_1)/v_1) \times 100$  to calculate the difference between the 1st and 10th diaphragmatic contraction velocity during a sniff nasal inspiratory pressure manoeuvre. They found a significant change between the 1st and 10th diaphragmatic contraction velocity in myasthenia gravis patients who need noninvasive ventilation (NIV) compared to those who did not. Further, percentage change in diaphragmatic contraction velocity inversely correlated with maximal inspiratory pressure. The authors concluded that ultrasound evaluation of diaphragmatic contraction velocity could be an effective tool in predicting diaphragmatic fatigability and so mechanical ventilation.

In the same context, GONZÁLEZ-POSADA *et al.* [40] assessed diaphragmatic contraction during the sniff test and deep breathing as well as the diaphragmatic thickness at both the end-inspiration and end-expiration in patients presenting with amyotrophic lateral sclerosis. The authors found that there was a significant positive correlation between pulmonary function tests (mainly forced vital capacity and maximal



inspiratory pressure) and diaphragmatic contraction, especially during deep breathing, as well as with diaphragmatic thickness. On the other hand, there was a significant inverse correlation between the same parameters as well as the calculated diaphragmatic thickness fraction and both base excess and  $\text{HCO}_3^-$  in arterial blood gases analysis. Accordingly, the authors concluded that diaphragmatic ultrasound is useful in assessing amyotrophic lateral sclerosis and could be a guide to functional deterioration.

Interestingly, LONGONI *et al.* [41] explored the role of diaphragmatic ultrasound as a part of educational programmes for patients with problems adapting to NIV. They studied 20 patients with NIV problems. They assessed diaphragmatic excursion breath by breath during spontaneous breathing and then with the NIV device while the patient was in a supine position at 45° with the monitor facing towards the patient. All the patients subsequently easily accepted the NIV machine. The authors concluded that incorporation of diaphragmatic ultrasound in patient educational programmes reinforces the use of NIV devices.

### Lung ultrasound

The use of lung ultrasound was discussed in different clinical setting during ERS Congress 2023. In a randomised trial, FALSTER *et al.* [42] examined whether focused lung, venous and cardiac ultrasound can reduce the rate of referral to CT pulmonary angiography in patients with suspected pulmonary embolism. In the focused ultrasound arm, CT pulmonary angiography was avoided in 45.2% of the included patients. Of the patients who had negative ultrasound findings, 6.7% developed pulmonary embolism on follow-up. The role of lung ultrasound in evaluating ILD was studied by GUPTA *et al.* [43], who enrolled 117 patients with systemic sclerosis under evaluation for possible ILD. Patients underwent lung function testing, lung ultrasound and CT scanning. Both the number of B lines and the presence of a broken pleura sign on lung ultrasound strongly correlated with the CT score for lung fibrosis, meaning that ultrasound could potentially have a role in the screening, diagnosis and follow-up of this patient population.

### New techniques in ultrasound

Elastography is an ultrasound mode measuring tissue stiffness and is an established test in the management of liver cirrhosis. The use of this mode in respiratory disease is evolving. Building on previous studies from the same laboratory, KUO *et al.* [44] examined the discriminative ability of pleural shear wave elastography (SWE) in differentiating benign from malignant lesions. In a study including 210 patients, SWE had an accuracy of 72% when a cut-off of 60.2 kPa was used to discriminate benign from malignant disease. WU *et al.* [45] examined multiple SWE-based assessments in patients presenting to the emergency department with new unilateral pleural effusion. In comparison to standard ultrasound findings of pleural malignancy (parietal or diaphragmatic pleural nodularity), which had high specificity (91%) and low sensitivity (29%), increased intercostal space stiffness on SWE had a sensitivity of 100%, but a specificity of 59%. These novel findings are promising for a more central role for elastography in pleural disease.

Another relatively new discipline for ultrasound is laryngeal and subglottic examination. HOU *et al.* [46] compared CT and ultrasound measurements of subglottic area diameter in 123 volunteers with normal airways and 15 patients with subglottic stenosis. A strong correlation was found between CT measurement and ultrasound-driven radius of curvature ( $r=0.96$ ,  $p<0.001$ ).

### Training in ultrasound

Abstracts presented at ERS Congress 2023 covered subjects such as validity evidence for the ERS Objective Structured Clinical Examination in thoracic ultrasound and training models for ultrasound-guided interventions [47, 48]. NIELSEN *et al.* [49] reported on the use of immersive virtual reality in assessing skill level in thoracic ultrasound using data from participants in a “Clinical Skills Zone” during ERS Congress 2022. The technology was useful in discriminating between operators with different skill levels.

### Concluding remarks

ERS Congress 2023 demonstrated that research in clinical techniques and imaging is rapidly progressing for diagnosing and treating benign as well as malignant diseases. Besides educational courses and workshops, studies in assessment of competencies were presented at this congress, ensuring evidence-based education in techniques encompassed by this assembly. The authors conclude that the ERS Congress is an absolute must for medical professionals interested in clinical techniques, imaging and endoscopy, and we are already looking forward to the 2024 ERS Congress sessions in Vienna.

Provenance: Commissioned article, peer reviewed.

Conflict of interest: A. Moretti was the winner of a research fellowship grant from SIP (Italian Respiratory Society), outside the submitted work; and reports support for attending meetings from Amsterdam UMC, outside the submitted work. P.I. Pietersen reports a grant from Boehringer Ingelheim for travel and accommodation for the European Society of Thoracic Imaging Winter Course 2022, outside the submitted work. H. Prosch reports research grants or contracts from Boehringer Ingelheim, AstraZeneca, Siemens Healthineers, the Christian Doppler Research Association and the EU Commission (EU4Health, Horizon Europe Health), outside the submitted work; payment or honoraria for lectures, presentations, speakers' bureaus, manuscript writing or educational events from AstraZeneca, BMS, Boehringer Ingelheim, Bracco, Daiichi Sankyo, Janssen, MSD, Novartis, Roche, Sanofi, Siemens Healthineers and Takeda, outside the submitted work; support for attending meetings and/or travel from Boehringer Ingelheim, outside the submitted work; and participation on a data safety monitoring or advisory board for BMS, Boehringer Ingelheim, Janssen, MSD, Roche and Sanofi, outside the submitted work. H. Shafiek reports a grant for a research fellowship from the Ministry of Higher Education and Scientific Research of Egypt to work in Spain for 6 months (April 2021 to October 2021), outside the submitted work; support from the ERS to attend the International Congress in Milan in 2023, outside the submitted work; and was leader of the bronchoscopy unit of Alexandria Faculty of Medicine, Egypt between October 2022 and September 2023, and is leader of the bronchoscopy unit of Smouha University Hospital, Alexandria, Egypt, from April 2023 to present, outside the submitted work. A.D. Tarnoki reports payment or honoraria for lectures, presentations, speakers' bureaus, manuscript writing or educational events from Boehringer Ingelheim, outside the submitted work; and is ERS Imaging Group chair 2022–2024. J.T. Annema reports support for the present manuscript from Mauna Kea Technologies and a grant from Mauna Kea Technologies, outside the submitted work. M. Munavvar reports honorarium for teaching from Olympus Europe, Becton Dickinson and Chiesi, outside the submitted work; and sponsorship for travel from Chiesi, outside the submitted work. P.I. Bonta reports institutional research grants from AstraZeneca, Mauna Kea and Boston Scientific, outside the submitted work. A.D. Juul reports research funding from Danish Cancer Society and Danish Center for Lung Cancer Research, outside the submitted work. All other authors have nothing to disclose.

## References

- 1 Kops SEP, Heus P, Korevaar DA, *et al.* Diagnostic yield and safety of navigation bronchoscopy: a systematic review and meta-analysis. *Lung Cancer* 2023; 180: 107196.
- 2 Verhoeven RLJ, Fütterer JJ, Hoefsloot W, *et al.* Cone-beam CT image guidance with and without electromagnetic navigation bronchoscopy for biopsy of peripheral pulmonary lesions. *J Bronchology Interv Pulmonol* 2021; 28: 60–69.
- 3 Bondue B, Taton O, Tannouri F, *et al.* High diagnostic yield of electromagnetic navigation bronchoscopy performed under cone beam CT guidance: results of a randomized Belgian monocentric study. *BMC Pulm Med* 2023; 23: 185.
- 4 Brock J, Dittrich S, Kontogianni K, *et al.* First European results: shape-sensing robotic assisted bronchoscopy for biopsy of peripheral lung nodules. *Eur Respir J* 2023; 62: Suppl. 67, OA2597.
- 5 Kramer T, Wijmans L, van Heumen S, *et al.* Needle-based confocal laser endomicroscopy for real-time granuloma detection. *Respirology* 2023; 28: 934–941.
- 6 Kramer T, van Heumen S, Wijmans L, *et al.* Needle based confocal laser endomicroscopy for real-time granuloma detection. *Eur Respir J* 2023; 62: Suppl. 67, PA4005.
- 7 Furuse H, Matsumoto Y, Nakai T, *et al.* Diagnostic efficacy of cryobiopsy for peripheral pulmonary lesions: a propensity score analysis. *Lung Cancer* 2023; 178: 220–228.
- 8 Lee-Mateus AY, Abia-Trujillo D, Barrios-Ruiz A, *et al.* Diagnostic yield of shape sensing robotic-assisted bronchoscopy for pulmonary nodules less than 2 cm pre and post-3D fluoroscopy. *Eur Respir J* 2023; 62: Suppl. 67, OA2599.
- 9 Nakai T, Watanabe T, Yamada K, *et al.* Diagnostic utility and safety of non-intubated cryobiopsy using a 1.1-mm cryoprobe for peripheral pulmonary lesions. *Eur Respir J* 2023; 62: Suppl. 67, PA468.
- 10 Zhong C-H, Sun J-Y, Su Z-Q, *et al.* A multi-center, prospective study of transbronchial radiofrequency ablation for peripheral lung tumors: study progress and initial results. *Eur Respir J* 2023; 62: Suppl. 67, OA2598.
- 11 Valipour A, Fernandez-Bussy S, Ing AJ, *et al.* Bronchial rheoplasty for treatment of chronic bronchitis. Twelve-month results from a multicenter clinical trial. *Am J Respir Crit Care Med* 2020; 202: 681–689.
- 12 Brock J, Herth F, Darwiche K, *et al.* Bronchial rheoplasty for chronic bronchitis: 6-month results from the European Registry Study. *Eur Respir J* 2023; 62: Suppl. 67, OA2594.
- 13 Orton CM, Tonkin J, Chan L, *et al.* Metered cryospray improves patient-reported outcome measures at 6-months post-crossover treatment, in patients with COPD with chronic bronchitis. *Eur Respir J* 2023; 62: Suppl. 67, PA4613.
- 14 Van Der Molen MC, Posthuma R, Hartman JE, *et al.* The impact and timing of pulmonary rehabilitation in patients undergoing bronchoscopic lung volume reduction with endobronchial valves: a randomized controlled trial in patients with severe emphysema. *Eur Respir J* 2023; 62: Suppl. 67, OA3252.

- 15 Roodenburg SA, Klooster K, Slebos D-J, *et al.* The impact of emphysema heterogeneity on treatment response after endobronchial valve treatment. *Eur Respir J* 2023; 62: Suppl. 67, PA4614.
- 16 Schuler S, Kontogianni K, Rötting M, *et al.* Lobar deflation predicts FEV<sub>1</sub> following valve therapy in patients with severe emphysema. *Eur Respir J* 2023; 62: Suppl. 67, PA4620.
- 17 Dittrich S, Unterschemmann A-S, Trudzinski F, *et al.* Combination of endobronchial and intrabronchial valves for endoscopic therapy of advanced emphysema. *Eur Respir J* 2023; 62: Suppl. 67, PA4618.
- 18 Kontogianni K, Valipour A, Eisenmann S, *et al.* Bronchoscopic thermal vapor ablation (BTVA) in patients with severe upper lobe predominant emphysema: 36 months follow-up results from a prospective registry. *Eur Respir J* 2023; 62: Suppl. 67, OA2593.
- 19 Korevaar DA, Colella S, Fally M, *et al.* European Respiratory Society guidelines on transbronchial lung cryobiopsy in the diagnosis of interstitial lung diseases. *Eur Respir J* 2022; 60: 2200425.
- 20 Hou G, Bian Y, Deng M. Use of 1.1-mm probes in transbronchial lung cryobiopsy for diagnosing interstitial lung diseases: a randomized trial. *Eur Respir J* 2023; 62: Suppl. 67, OA1426.
- 21 Freund O, Wand O, Schmeer S, *et al.* Trans-bronchial cryobiopsy is superior to forceps biopsy for diagnosing both fibrotic and non-fibrotic interstitial lung diseases. *Eur Respir J* 2023; 62: Suppl. 67, PA1730.
- 22 Soldati T, Vaselli M, Mooij-Kalverda KA, *et al.* In vivo endobronchial-PS-OCT for fibrosis quantification in ILD. *Eur Respir J* 2023; 62: Suppl. 67, OA4850.
- 23 Hendrix W, Rutten M, Hendrix N, *et al.* Trends in the incidence of pulmonary nodules in chest computed tomography: 10-year results from two Dutch hospitals. *Eur Radiol* 2023; 33: 8279–8288.
- 24 European Council. Council Updates its Recommendation to Screen for Cancer. Date last updated: 9 December 2022. Date last accessed: 24 October 2023. <https://www.consilium.europa.eu/en/press/press-releases/2022/12/09/council-updates-its-recommendation-to-screen-for-cancer/>
- 25 Ewals LJS, van der Wulp K, van den Borne B, *et al.* The effects of artificial intelligence assistance on the radiologists' assessment of lung nodules on CT scans: a systematic review. *J Clin Med* 2023; 12: 3536.
- 26 Chao HS, Tsai CY, Chou CW, *et al.* Artificial intelligence assisted computational tomographic detection of lung nodules for prognostic cancer examination: a large-scale clinical trial. *Biomedicines* 2023; 11: 147.
- 27 Pehrson LM, Nielsen MB, Ammitzbøl Lauridsen C. Automatic pulmonary nodule detection applying deep learning or machine learning algorithms to the LIDC-IDRI database: a systematic review. *Diagnostics (Basel)* 2019; 9: 29.
- 28 National Institute for Health and Care Excellence. AI-Derived Computer-Aided Detection (CAD) Software for Detecting and Measuring Lung Nodules in CT Scan Images. Date last updated: 5 July 2023. Date last accessed: 24 October 2023. [www.nice.org.uk/guidance/dg55/resources/aidderived-computeraided-detection-cad-software-for-detecting-and-measuring-lung-nodules-in-ct-scan-images-pdf-1053873334213](http://www.nice.org.uk/guidance/dg55/resources/aidderived-computeraided-detection-cad-software-for-detecting-and-measuring-lung-nodules-in-ct-scan-images-pdf-1053873334213)
- 29 Ciompi F, Chung K, van Riel SJ, *et al.* Towards automatic pulmonary nodule management in lung cancer screening with deep learning. *Sci Rep* 2017; 7: 46479.
- 30 Venkadesh KV, Setio AAA, Schreuder A, *et al.* Deep learning for malignancy risk estimation of pulmonary nodules detected at low-dose screening CT. *Radiology* 2021; 300: 438–447.
- 31 Mikhael PG, Wohlwend J, Yala A, *et al.* Sybil: a validated deep learning model to predict future lung cancer risk from a single low-dose chest computed tomography. *J Clin Oncol* 2023; 41: 2191–2200.
- 32 Casagrande G, Chiarantano RS, Siqueira AP, *et al.* Fluid specific miRNA-based signatures for lung cancer screening. *Eur Respir J* 2023; 62: Suppl. 67, OA3267.
- 33 Zwijsen K, Wener R, Janssens E, *et al.* Exhaled breath analysis optimizes nodule management in a lung cancer screening program. *Eur Respir J* 2023; 62: Suppl. 67, OA3265.
- 34 Kikano GE, Fabien A, Schilz R. Evaluation of the solitary pulmonary nodule. *Am Fam Physician* 2015; 92: 1084–1091.
- 35 Murrmann GB, van Vollenhoven FH, Moodley L. Approach to a solid solitary pulmonary nodule in two different settings – “Common is common, rare is rare”. *J Thorac Dis* 2014; 6: 237–248.
- 36 O'Dowd EL, Baldwin DR. Lung nodules: sorting the wheat from the chaff. *Br J Radiol* 2023; 96: 20220963.
- 37 American College of Radiology. Lung-RADS v2022. Date last updated: November 2022. Date last accessed: 24 October 2023. [www.acr.org/-/media/ACR/Files/RADS/Lung-RADS/Lung-RADS-2022.pdf](http://www.acr.org/-/media/ACR/Files/RADS/Lung-RADS/Lung-RADS-2022.pdf)
- 38 SOLACE: Strengthening the Screening of Lung Cancer in Europe. Date last accessed: 24 October 2023. <https://europeanlung.org/solace/>
- 39 Espinosa SF, Reynoso AQ, Sancho J, *et al.* Diaphragmatic contraction speed at follow-up of patients admitted for myasthenia gravis. *Eur Respir J* 2023; 62: Suppl. 67, PA1815.
- 40 González-Posada IM, Hernández JC, Cuesta PL, *et al.* Use of diaphragmatic ultrasound to evaluate respiratory function in patients with amyotrophic lateral sclerosis. *Eur Respir J* 2023; 62: Suppl. 67, PA1816.
- 41 Longoni A, Bassino C, Cappelletti T, *et al.* Diaphragm sonography as an educational aid in CPAP and NIMV treatment. *Eur Respir J* 2023; 62: Suppl. 67, PA1822.
- 42 Falster C, Nielsen RW, Møller JE, *et al.* Does ultrasound in suspected pulmonary embolism safely reduce referral to diagnostic imaging? A randomized controlled trial. *Eur Respir J* 2023; 62: Suppl. 67, RCT3216.

- 43 Gupta R, Davis JKJ, Nair A, *et al.* Role of lung ultrasound in detection and assessment of severity of ILD in patients with systemic sclerosis. *Eur Respir J* 2023; 62: Suppl. 67, PA1821.
- 44 Kuo Y-W, Chen Y-L, Wu H-D, *et al.* Validation of transthoracic shear-wave ultrasound elastography in diagnosing pleural lesions. *Eur Respir J* 2023; 62: Suppl. 67, PA1831.
- 45 Wiig R, Falster C, Jacobsen N, *et al.* Diagnostic accuracy of lung ultrasound with elastography in predicting malignant origin of pleural effusions in an emergency department. *Eur Respir J* 2023; 62: Suppl. 67, PA1824.
- 46 Hou G, Lin J, Deng M. Point-of-care ultrasound for the assessment of subglottic and cervical tracheal stenosis: a prospective, multicenter, exploratory study. *Eur Respir J* 2023; 62: Suppl. 67, PA1830.
- 47 Pietersen PI, Bhatnagar R, Andreassen F, *et al.* Validity evidence of the 2022 ERS thoracic ultrasound Objective Structured Clinical Examination (OSCE). *Eur Respir J* 2023; 62: Suppl. 67, PA1814.
- 48 Gilbert C, Ortiz R, Ma Y, *et al.* Transbronchial needle aspiration (TBNA): past, present and future. *Curr Respir Med Rev* 2014; 10: 176–181.
- 49 Nielsen AB, Jacobsen N, Laursen C, *et al.* Assessment of thoracic ultrasound skills in immersive virtual reality. *Eur Respir J* 2023; 62: Suppl. 67, PA492.