

Central Lancashire Online Knowledge (CLOK)

Title	Renal protective effect of Trigonella foenum-graecum seed extract on morphine withdrawal in rats
Type	Article
URL	https://clock.uclan.ac.uk/45132/
DOI	10.51248/.v42i6.2008
Date	2022
Citation	Sharminni A/P Krishnan, Sutha, Jeppu, Ashok Kumar, Halim, Shariff, Sina Alkesah, Thur, Ashok Kumar, Kavitha and Soni, Gargi (2022) Renal protective effect of Trigonella foenum-graecum seed extract on morphine withdrawal in rats. Biomedicine, 42 (6). pp. 1172-1177. ISSN 0970-2067
Creators	Sharminni A/P Krishnan, Sutha, Jeppu, Ashok Kumar, Halim, Shariff, Sina Alkesah, Thur, Ashok Kumar, Kavitha and Soni, Gargi

It is advisable to refer to the publisher's version if you intend to cite from the work.
10.51248/.v42i6.2008

For information about Research at UCLan please go to <http://www.uclan.ac.uk/research/>

All outputs in CLOK are protected by Intellectual Property Rights law, including Copyright law. Copyright, IPR and Moral Rights for the works on this site are retained by the individual authors and/or other copyright owners. Terms and conditions for use of this material are defined in the <http://clock.uclan.ac.uk/policies/>

Research article

Renal protective effect of *Trigonella foenum-graecum* seed extract on morphine withdrawal in rats

Sutha Sharminni A/P Krishnan¹, Ashok Kumar Jeppu², Shariff Halim³, Thur Sina Alkesah⁴,
Kavitha Ashok Kumar⁵, Gargi Soni⁶

^{1,4} Clinical Research Centre, Management and Science University, University Drive, Off Persiaran Olahraga, Shah Alam, Selangor, Malaysia

²Biochemistry Unit, ³Neuroscience Research Group, ⁵Otorhinolaryngology, International Medical School, Management and Science University, University Drive, Off Persiaran Olahraga, 40100 Shah Alam, Selangor, Malaysia

⁶Gross Anatomy, School of Medicine, University of Central Lancashire, Preston, United Kingdom

(Received: August 2022

Revised: November 2022

Accepted: December 2022)

Corresponding author: Ashok Kumar Jeppu. Email: drashokkumarj@gmail.com

ABSTRACT

Introduction and Aim: Morphine is widely used as a drug for treating chronic pain in post-operative and cancer patients. Unfortunately, over time, prolonged use of morphine can cause nephrotoxicity due to elevated level of oxidative stress. *Trigonella foenum-graecum* (TFG) commonly known as 'fenugreek' is well-known for its antioxidative properties. This study evaluated the renal protective effects of TFG on the morphine induced rats.

Materials and Methods: Male Sprague Dawley rats were divided into 5 Groups (n=8). The positive control and treatment Groups were administered morphine intraperitoneally for 7 consecutive days. The treatment Groups were administered aqueous extract of TFG orally for 21 days. The weight of the kidneys was measured, and histological changes were studied. The oxidative stress in the kidney tissue was studied by measuring the malondialdehyde (MDA), superoxide dismutase (SOD), total antioxidant capacity (TAC) and glutathione (GSH) in the tissue homogenate.

Results: The kidney weights were significantly reduced in morphine administered rats compared to the aqueous TFG extract treated Groups. Histological examinations revealed a greater number of healthy glomeruli and thick renal tubules in the aqueous TFG extract treated rats. In morphine administered rats, the oxidative stress was higher with the MDA level significantly increased while the levels of SOD, TAC and GSH were reduced compared to normal rats.

Conclusion: The aqueous TFG extract treatment reduced the oxidative stress in the kidneys of the morphine administered rats. The nephroprotective effects of aqueous TFG extract may be related to its antioxidant activity.

Keywords: Fenugreek; kidney; morphine; oxidative stress; *Trigonella-foenum graecum*.

INTRODUCTION

Morphine is widely used as an analgesic drug for treating chronic pain caused by cancer and lesions in the central nervous system (1,2). This action of morphine is due to its potential to suppress the pain by inhibiting the pain impulse transmission in the spinal cord and by regulating the central pain processing(3). This analgesic property of morphine allows it to remain as the gold standard opioid therapy (4). Morphine is one of the naturally occurring alkaloids in opium poppy.

Oxidative Stress is defined by a condition characterized by imbalance in the levels of antioxidants and oxidants. This condition can arise due to the excessive production of reactive oxygen species (ROS) and reactive nitrogen species (RNS; 5). Concurrently, chronic morphine administration has the potential to trigger oxidative damage in various organs due to production of excessive free radicals' as a result of toxicity induced by opioid drugs. Jalili et

al., in 2019, stated that chronic morphine administration can cause lipid peroxidation, damage in antioxidant defence systems and destruction of the organs structure and functions (6).

The fenugreek with scientific name *Trigonella foenum-graecum* (TFG), belonging to the family *Fabaceae* is a leguminous plant. This plant's leaves have trifoliate shape and flowers usually range from white to yellow in colour. The plant has thin and pointed beaked pods that have about an average of 3 to 15 cm length. Importantly, the plant produces oblong shaped seeds which are greenish-brown in colour with hooplike grooves (7). India and North African countries are considered as the origin of this plant (7). Fenugreek seeds which are eaten raw or cooked are aromatic with bitter taste. They have flatus-relieving, lactation stimulating and antibacterial properties. The antioxidant potential of fenugreek seeds are due to its bioactive compounds such as polysaccharides, flavonoids and polyphenols (8,9).

METHODOLOGY

The fenugreek seeds (TFG) were bought from a local store in Shah Alam, Selangor. The fenugreek seeds were washed, cleaned and oven-dried with the temperature set at 57°C for about 40 minutes. The dried fenugreek seeds then were grounded into a fine powder using a grinding machine. The seed powder of about 50 g was mixed with 500 mL of distilled water with the use of spatula. The mixture was boiled for 30 minutes and stirred for another 30 minutes with the use of a hot plate and stirrer. The mixture was then filtered with the use of strainer and later with filter paper. The filtrate obtained then was concentrated under a reduced pressure with the use of a rotary evaporator for two hours to get a yield. The pure crude extract of fenugreek seed obtained was placed in a small bottle and stored in a cold room (2-8°C; 10).

A total of fifty male Sprague Dawley rats were used for this experiment with the average of weight about 115 grams to 125 grams.

$E = \text{total number of animals} - \text{total number of Groups}$

$E = [10 \times 5] - 5 ; E = 45$

The minimum number of necessary sample size was 20, hence 45 is more than the minimum number (11).

The rats were stationed in the animal house of university and maintained under controlled condition with $23 \pm 1^\circ\text{C}$, 12 hours light/dark cycle, relatively humid environment [30-40%] and free access of food and water. The guideline for animal studies endorse by the university were followed the Ethics Committee approval [Code ethic: MSU-RMC-02/FR01/08/L3/014]. At the end of the study, the rats were sacrificed using decapitation method and their kidneys were collected (12). The drug used in this study was Morphine sulfate [10 mg/kg] purchased from Merck, Germany. Morphine was injected to the rats via intraperitoneal route with gradual increasing dose. On the first day, the rats were injected intraperitoneally 10 mg/kg morphine twice a day [at 08.00 AM and 05.00 PM] to make them dependent on morphine. Thereafter 2.5 mg/kg incremental dose per day of morphine was injected. The doses were increased until a maximum of 50 mg/kg twice a day was reached for the total duration of 30 days (12).

Experimental groups

The rats were divided into 5 experimental Groups and each comprising of 10 rats (12):

- Group 1 (negative control): The rats were given normal saline orally 7 days consecutively.
- Group 2 (positive control): Variable doses of morphine were given to the rats via intraperitoneal injection for 7 consecutive days from 2.5 mg/kg until a maximum 50 mg/kg.

- Group 3 (Treatment Group 3): Variable doses of morphine solution were given to the rats via intraperitoneal injection for 7 consecutive days from 2.5 mg/kg until a maximum 50 mg/kg followed by 250 mg/kg of *Trigonella foenum-graecum* extraction given orally for 21 consecutive days.
- Group 4 (Treatment Group 4): Variable doses of morphine solution were given to the rats via intraperitoneal injection for 7 consecutive days from 2.5 mg/kg until a maximum 50 mg/kg followed by 500 mg/kg subsequently were supplemented with *Trigonella foenum-graecum* orally as a treatment for 21 consecutive days.
- Group 5 (Treatment Group 5): Variable doses of morphine solution were given to the rats via intraperitoneal injection for 7 consecutive days from 2.5 mg/kg until a maximum 50 mg/kg. Then, their oral treatment with *Trigonella foenum-graecum* extraction of about 1000 mg/kg for 21 days was achieved.

After 21 days of aqueous TFG extract treatment, rats were sacrificed by cervical decapitation to harvest the kidneys. Ice-cold Phosphate-Buffered Saline [PBS] [0.01 M, pH = 7.4] was used to rinse the excess blood from the tissue samples. After processing the tissue samples a solidified paraffin blocks were prepared, and they were sectioned using a microtome which was later stained with haematoxylin and eosin staining. The stained sections were observed under a light microscope.

The rats' kidneys from all the five groups were rinsed in ice-cold PBS (0.01M, pH=7.4) to remove the excess blood thoroughly. The kidneys were homogenized in PBS (tissue weight (g): PBS (mL) volume = 1:9) with a tissue homogenizer. The homogenates were then centrifuged for 5 min at 5000 xg to get the supernatant. The determination of superoxide dismutase (SOD), total antioxidant capacity (TAC), glutathione (GSH) and malondialdehyde (MDA) levels were carried out by using ELISA kits. The comparison between the independent samples was done by utilizing the independent Student's t-test while one way ANOVA was used to make comparisons between more than two groups (analysis of variance) via Statistical Package Social Science [SPSS] version 23 (13).

RESULTS

The weights of the kidneys were listed in Table 1. The rats' kidneys from all groups were stained with haematoxylin and eosin staining and examined under light microscope 40X. Rats' kidney from Group 1 showed normal, healthy, and numerous renal corpuscles and tubules. The Group 2 revealed a reduced number, increase in the diameter of glomeruli

and increase in the thickness of renal tubules in the rat's kidney. However, the Group 3 showed less number of glomeruli with slight increase in the glomerular diameter and renal tubules with a slight increase in thickness. Group 4 showed increased number of glomeruli along with renal tubules having normal morphology, without thickening of the cells lining the tubules. Group 5 showed healthy glomeruli but less in number, along with renal tubules with increased thickness and narrow lumen (Fig. 1).

Repeated administration of morphine significantly ($p<0.05$) increased the MDA level in Group 2 when compared to Group 1. However, the Post hoc test for

comparison between the Groups had shown significant ($p<0.05$) decreased the MDA in the kidney of Group 3 compared with Group 2 rats (Table 3). A significant ($p<0.05$) difference is found in the SOD activity, GSH levels and TAC of the rat's kidney between different Groups (Table 2). The post hoc test for comparison between the Groups revealed that the significant; difference in the level of SOD between the Group 2 and Group 4; GSH level was significantly ($p<0.05$) increased in all treatment Groups (Group 3,4 and 5) when compared to Group 2 (Table 3). TAC activity was also increased significantly ($p<0.05$) in Group 3 and Group 4 rats treated with aqueous extract of TFG when compared to Group 2 (Table 3).

Table 1: Total kidney weight of rats of each Group

Group	Sum of Left and Right Kidneys								Total Kidney Weight
	Rat 1	Rat 2	Rat 3	Rat 4	Rat 5	Rat 6	Rat 7	Rat 8	
Group 1	1.78	2.1	1.96	1.26	2.15	1.04	1.23	1.19	12.71
Group 2	2.22	2.21	2.01	2.17	1.67	1.97	2.16	2.07	16.49
Group 3	1.94	1.87	2.31	1.69	2.11	1.71	1.52	2.62	16.77
Group 4	1.68	2.79	2.19	2.18	1.86	2.02	2.24	1.95	16.91
Group 5	1.63	2.66	1.59	2.71	1.98	2.04	2.08	2.52	23.21

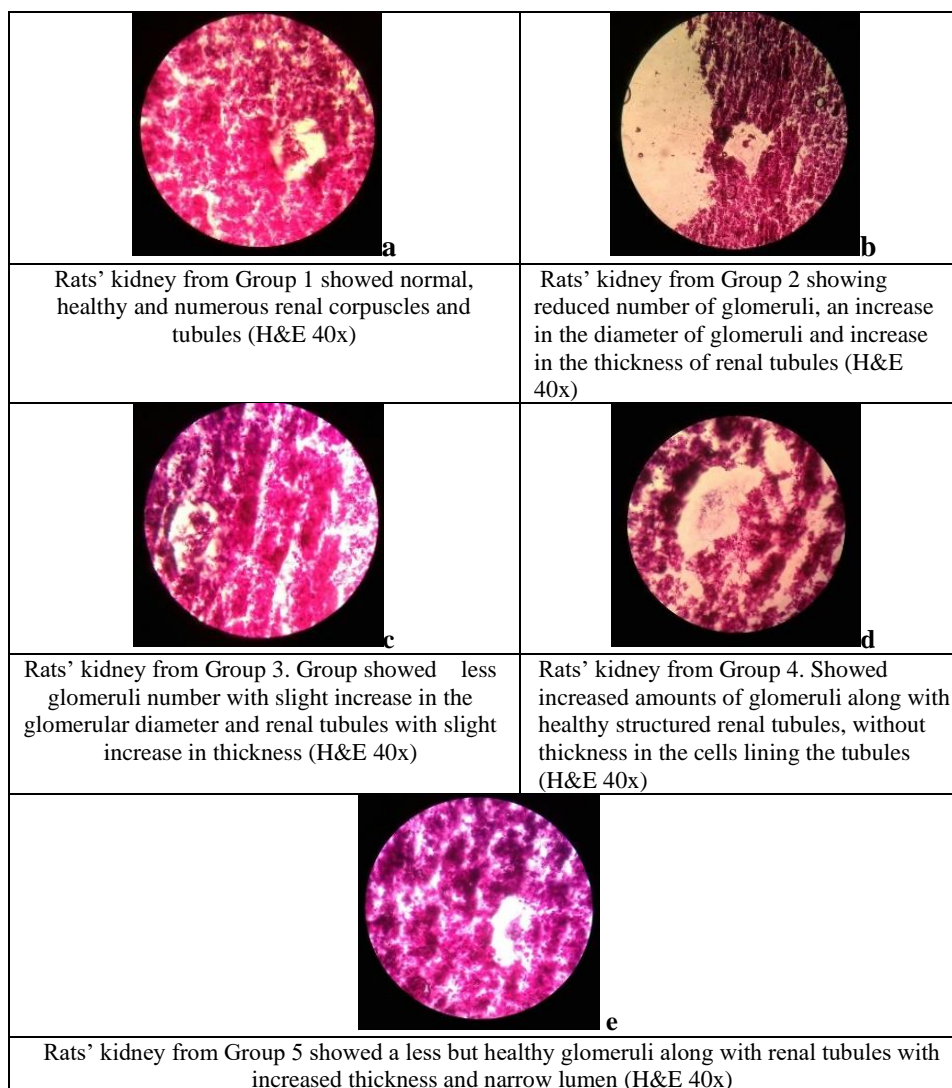


Fig. 1: Histological observations of rat kidney in different groups

Table 2: Comparison of oxidative stress parameters in the kidney homogenate of different groups of rats

Group	Mean	SE	95% confidence		F value	p value
			Upper bound	Lower bound		
Total antioxidant activity						
Group 1	4.196	0.563	1.774	6.619	12.187	0.001*
Group 2	2.726	0.238	1.699	3.754		
Group 3	11.880	3.048	-1.2374	24.997		
Group 4	15.760	0.786	12.375	19.144		
Group 5	8.054	1.518	-0.823	12.243		
GSH						
Group 1	156.75	8.35	130.18	183.32	6.081	0.004*
Group 2	111.25	1.10	107.72	114.78		
Group 3	157.00	10.01	124.57	189.43		
Group 4	170.25	13.33	127.82	212.68		
Group 5	169.50	11.36	133.34	205.66		
Superoxide Dismutase (SOD)						
Group 1	721.87	10.82	675.31	768.43	3.979	0.035*
Group 2	400.57	154.55	-264.41	1065.55		
Group 3	868.98	119.56	358.85	1379.12		
Group 4	1027.07	81.68	675.59	1378.55		
Group 5	815.97	152.81	158.46	1473.48		
MDA						
Group 1	1639.57	68.57	768.30	2510.83	6.113	0.037*
Group 2	2765.37	215.84	22.86	5507.88		
Group 3	1094.00	487.00	-5093.90	7281.92		
Group 4	1660.48	50.52	1018.49	2302.46		
Group 5	1602.26	241.502	1055.95	2148.58		

* Significant at ≤ 0.05 level**Table 3:** Comparison of the dependent variables between the morphine treated group and different treatment Groups by Post Hoc Test

Dependent variable	Groups		Mean difference	p value
MDA	Group 2	Group 3	1671.37	0.053
		Group 4	1104.90	0.202
		Group 5	1913.50	0.031*
SOD	Group 2	Group 3	-468.41	0.100
		Group 4	-626.50	0.023*
		Group 5	- 415.40	0.162
GSH	Group 2	Group 3	-45.8	0.034*
		Group 4	-59.0	0.005*
		Group 5	-58.0	0.006*
TAC	Group 2	Group 3	-9.153	.015*
		Group 4	-13.03	.001*
		Group 5	-2.98	.681

* The mean difference significant at ≤ 0.05 level

DISCUSSION

Morphine is widely used as a drug for treating chronic pain caused by post-operations and cancer (1). Long term administration of morphine can develop morphine addiction and if the amount of opioid drug intake is reduced or when changed to the use of other opioid drug therapy, withdrawal symptoms can manifest. Chronic administration of morphine can also cause the excessive production of free radicals and that can eventually bring oxidative damage to other organs such as the kidney (6). However, the plant called fenugreek, that has a scientific name *Trigonella foenum-graecum*, is well known for its antioxidative properties, due the

presence of polysaccharides, flavonoids and polyphenols (8). Therefore, the purpose of this study is to evaluate the renal protective effects of fenugreek seeds on the morphine withdrawal rats.

The rats' kidney weight measurement was taken in order to determine the changes in the organ weight and to make comparisons among the *Trigonella foenum-graecum* (TFG) treated and untreated rats. The long-term administration of morphine can cause changes in the weight of the kidney. When morphine is chronically abused, the kidney can undergo reduction in its size and weight (6). The rats from the negative control group (Group 1) exhibited a significant reduction in their kidney weight. The rats

from positive control group (Group 2), which received only morphine injection and developed withdrawal symptoms, showed a significant decrease in their kidney weight measurement, compared to the rats' kidneys from TFG treatment groups (Groups 3,4 and 4). Jalili *et al.*, mentioned that the chronic morphine administration causes decrease in the kidney weight due to the release of dopamine, serotonin and γ -amino butyric acid that functions in suppressing the appetite and enhancing the rate of metabolism (6). The rats from TFG treatment groups showed a significant increase in their kidney weight measurement, compared to the rats' kidney from Group 1 and Group 2 rats. The rats' kidneys weight measurement showed a gradual increase in the treatment groups (Group 3 to Group 5). Since, rats in Group 5 received the aqueous extract of TFG of about 1000 mg/kg and showed a significant increase in their kidney weight measurement, it is clear that the more the amount of aqueous extract of TFG seed the rats received, the higher the increase in their kidney weight. Therefore, it is obvious that the TFG treatment to the rats, has improved their kidney weight, despite the morphine injection.

The histological examination of the kidney of Group1 rats showed a normal, healthy and numerous renal corpuscles and tubules (Fig. 2). Remarkably, the renal tubules of rats' kidneys from positive control group (Group 2), appear thicker with small spaced lumen within. In an article written by Luo *et al.*, it is found that chronic administration of morphine has potential to trigger oxidative damage and cellular apoptosis in the kidney (14). Additionally, the article of Jalili *et al.*, 2019 stated that the oxidative stress generated by morphine is due to the stimulated cytochrome P450 that in turn produces excessive free radicals. As a result, these free radicals damage the proteins and DNA of renal cells and induce cellular apoptosis. The renal tubules showed an increased in thickness with narrow lumen, upon morphine administration, because morphine has the potential to stimulate the release of noradrenaline in the paraventricular and amygdala nucleus and by direct influence on the solitary nuclei to generate nitric oxide. Nitric oxide then allows the massive entry of calcium into the cytosol of cells and thereby induce toxic effects on the cells affected. The presence of nitric oxide synthase (NOS) isoforms such as iNOS, can increase the thickness of the proximal tubule, distal tubule and collecting ducts, and eventually facilitate the progression to nephrotoxicity, nephritic disease and nephrotic disease (6).

The histological examination of rats' kidneys from treatment groups (Groups 3, 4 and 5) showed the signs of recovery from the cellular damages caused by morphine administration Fig. 1. There was an increase in the number of glomeruli along with

healthy structured renal tubules, without thickness in the cell lining the tubules and alteration in the lumen size. Similar histological changes in the kidney caused by gentamicin were restored by the treatment with germinated fenugreek, and thus, it indicates a concomitant increase in antioxidant activity of fenugreek, according to Darwish (15). Badr stated that fenugreek treatment to the alloxan diabetic rats maintained the renal architecture as it succeeded to improve the histological parameters (16).

Besides, when all the histological findings of rats' kidneys from treatment groups including were compared, the rats' kidneys from Group 4 showed a better architecture with increased number of healthy glomeruli and normal renal tubules. The widely spaced lumen in the renal tubules indicates the proximal convoluted tubules. Therefore, TFG treatment with the dose of 500 mg/kg is identified as the optimum dose for the better results. This is because the low dosage of TFG of about 250 mg/kg from Group 3 and the high dosage of TFG of about 1000 mg/kg from Group 5, failed to restore the histopathological changes caused by morphine in 21 days of daily TFG treatment.

The SOD activity, TAC and GSH concentration were significantly reduced in the kidney homogenates of rats of positive control group (Group 2), which received only morphine administration. This is because morphine administration causes excessive production of free radicals, and leads to oxidative stress and deteriorates the antioxidant status. Therefore, the level of antioxidants such as SOD, TAC and GSH were significantly reduced, indicating their depletion in neutralizing the free radicals (17). However, MDA concentration was significantly increased in positive control (Group 2), the morphine-administered rats' group, because the MDA concentration indicates the oxidative stress in the rat's kidney. According to Samarghandian *et al.*, lipid peroxidation is indicated in the kidney homogenates with the increase in MDA concentration (18). However, in the treatment groups, the levels of antioxidants such as SOD, TAC and GSH concentration were significantly increased, whereas the MDA concentration was significantly reduced. According to Darwish the fenugreek treatment caused restoration in the antioxidant status and managed to counterbalance the oxidative stress. The improved antioxidant status of the kidney caused the levels of SOD, TAC and GSH to elevate and MDA concentration to decline due to diminished lipid peroxidation (15,17).

Generally, superoxide dismutase (SOD) is an antioxidant enzyme that is present almost in all oxygen-metabolizing cells. This enzyme functions to protect cells from excessive superoxide. Besides that, TAC refers to the cumulative effect of antioxidant system, which includes enzymes antioxidant system

such as catalase (CAT), glutathione peroxidase (GSH-Px) and non- enzymatic antioxidant system such as uric acid, vitamin C, bilirubin, and carotenoid whereas, glutathione (GSH) is well known as the master of antioxidant in the body. It works as a primary antioxidant in eliminating excessive free radicals and thus, considered as a part of a natural defence system of the body (4). Malondialdehyde (MDA) is a by-product of oxidative damage by free radicals that act as a marker for oxidative stress, notably the lipid peroxidation.

Furthermore, when the three treatment Groups were compared, the rat's kidney homogenates from Group 4 showed the highest level of SOD, TAC and GSH, indicating that the TFG treatment with the dosage of 500 mg/kg as the optimum dose for the best results, because it succeeded to exhibit the highest antioxidant level in the morphine-induced rats, in 21 days of daily TFG treatment.

Trigonella foenum-graecum (TFG) or fenugreek seeds are rich sources of polysaccharides, flavonoids, and polyphenols, which play a vital role in exhibiting antioxidative function. Therefore, it is understood that the oxidative stress caused by morphine in the kidney is alleviated by the action of antioxidative compounds in the fenugreek seeds (8). Hence, fenugreek treatment helps to overcome opioid dependence by protecting the renal cells from toxicity and damage.

CONCLUSION

In conclusion, this study was carried out to reaffirm the nephroprotective effect of *Trigonella foenum-graecum* (TFG) seed extract by countering oxidative stress in morphine dependent rat models. The result of this study proves that TFG has the potential to act as antioxidative agent in order to reduce the oxidative stress by enhancing the antioxidant status, which has been proven by improving the histological architecture of renal cells, elevating the levels of SOD, TAC, GSH and reducing the concentration of MDA. Thus, this study has highlighted a new potential of TFG extract as a nephroprotective agent due to the inherent antioxidant and free-radical scavenging activity. However, further investigations are required for clinical studies to increase the understanding of the properties of TFG in humans as a nephroprotective agent.

ACKNOWLEDGMENT

We thank the Management and Science University for providing the facilities and seed grants (SG-034-012019-IMS) to conduct this research.

CONFLICT OF INTEREST

Authors declare no conflicts of interest.

REFERENCES

- Listos, J., Łupina, M., Talarek, S., Mazur, A., Orzelska-Górka, J., Kotlińska, J. The mechanisms involved in morphine addiction: An overview. Vol. 20, International Journal of Molecular Sciences. 2019; 20(17):4302.
- Wang, B., Su, C.J., Liu, T.T., Zhou, Y., Feng, Y., Huang, Y, et al., The neuroprotection of low-dose morphine in cellular and animal models of Parkinson's disease through ameliorating endoplasmic reticulum (ER) stress and activating autophagy. Frontiers in molecular neuroscience. 2018; 20 (11): 120-138.
- Skrabalova, J., Drastichova, Z., Novotny, J. Morphine as a potential oxidative stress-causing agent. Mini Rev Org Chem. 2013;10(4): 367-372.
- Lobo, EP., Pellegrini, F., Pusceddu, E. Anesthesia Complications in head and neck surgery. Complications in Head and Neck Surgery. 2nd edition, Philadelphia: Mosby Elsevier, 2009; 3-27.
- Mulgund, A., Doshi, S., Agarwal, A. The Role of Oxidative Stress in Endometriosis. Hand book of Fertility. Academic Press: 2015; 273-281.
- Jalili, C., Roshankhah, S., Salahshoor, M.R. Harmine recovers kidney damage induced by morphine in male rats. Iran J Pharmacol Ther. 2019; 17(1): 1-8.
- Srinivasan, K. Fenugreek (*Trigonella foenum-graecum*): A Review of Health Beneficial Physiological Effects Food reviews international; 2006; 22(2): 203-224.
- Mbarki, S., Alimi, H., Bouzenna, H., Elfeki, A., Hfaiedh, N. Phytochemical study and protective effect of *Trigonella foenum graecum* (Fenugreek seeds) against carbon tetrachloride-induced toxicity in liver and kidney of male rat. Biomed Pharmacother. 2017; 88: 19-26.
- Halim, S., Alkesah, TS., Krishnan, SSAP., Jeppu, AK. *Trigonella Foenum-Graecum* Seeds as a Potential Alternative Neuroprotect Agent against Morphine Dependence in Rat. 2021; 25(6): 432-434.
- Arshadi, S., Azarbayjani, MA., Hajiaghaalipour, F., Yusof, A., Peeri, M., Bakhtiyari, S., et al., Evaluation of *Trigonella foenum-graecum* extract in combination with swimming exercise compared to glibenclamide consumption on type 2 Diabetic rodents. 2015; 1: 1-9.
- Charan, J., Kantharia, N. How to calculate sample size in animal studies? J Pharmacol Pharmacother. 2013; 4(4): 303-306.
- Halim, S., Mohamad, N., Toriman, ME., Bakar, NHA., Hashim, SN., Adnan, L.H.M., et al., Role of Zamzam water as a vital mineral supplement in the treatment of opioid dependence and tolerance: a review. Res J Pharm Technol. 2016; 9(7): 957-963.
- Sumathi, T., Nathiya, V., Sakthikumar, M. Protective Effect of Bacoside-A against Morphine- Induced oxidative stress in rats. Indian J Pharm Sci. 2011; 73(4): 409-415.
- Luo, FC., Zhao, L., Deng, J., Liang, M., Zeng, XS., Liu, H., et al., Geranylgeranylacetone protects against morphine-induced hepatic and renal damage in mice. Mol Med Rep. 2013; 7(2): 694-700.
- Darwish, MM., Shaalan, S., Amer, MA., Hamad, SR. Ameliorative effects of dried and germinated fenugreek seeds on kidney failure induced by gentamicin in male mice. Am. J. Biomed. Sci. & Res. 2020; 9(6): 459-467.
- Badr, MI. Effect of fenugreek seeds on kidney structure and some physiological parameters in rats. Middle East J Appl Sci. 2017; 07: 967-973.
- Sushma, N., Devasena, T. Aqueous extract of *Trigonella foenum graecum* (fenugreek) prevents cypermethrin-induced hepatotoxicity and nephrotoxicity. Hum Exp Toxicol. 2010; 29(4): 311-319.
- Samarghandian, S., Afshari, R., Farkhondeh, T. Original Article Effect of long-term treatment of morphine on enzymes, oxidative stress indices and antioxidant status in male rat liver. Int J Clin Exp Med. 2014; 7(5): 1449-1453.