

## Central Lancashire Online Knowledge (CLoK)

Title	Myocardial Deformation Imaging Meta-Analysis in Two Cohorts of Patients from UAE and Heart Hospital Hamadmedical Corporation: A Potential Role in Assessment of Coronary Artery Disease Severity and Myocardial Viability
Type	Article
URL	<a href="https://clock.uclan.ac.uk/34562/">https://clock.uclan.ac.uk/34562/</a>
DOI	10. 35248/2155-9880.20.11.665
Date	2020
Citation	Allah, Sherif A Baath, Elmahal, Mohammed, Askar, Mohamed H, Singh, Jaipaul, Khorshid, Mohamed H, Lohana, Petras, Fedacko, Jan and Elkilany, Galal E Nagib (2020) Myocardial Deformation Imaging Meta-Analysis in Two Cohorts of Patients from UAE and Heart Hospital Hamadmedical Corporation: A Potential Role in Assessment of Coronary Artery Disease Severity and Myocardial Viability. Journal of Clinical and Experimental Cardiology, 11 (659). pp. 1-10. ISSN 2155-9880
Creators	Allah, Sherif A Baath, Elmahal, Mohammed, Askar, Mohamed H, Singh, Jaipaul, Khorshid, Mohamed H, Lohana, Petras, Fedacko, Jan and Elkilany, Galal E Nagib

It is advisable to refer to the publisher's version if you intend to cite from the work. 10. 35248/2155-9880.20.11.665

For information about Research at UCLan please go to <http://www.uclan.ac.uk/research/>

All outputs in CLoK are protected by Intellectual Property Rights law, including Copyright law. Copyright, IPR and Moral Rights for the works on this site are retained by the individual authors and/or other copyright owners. Terms and conditions for use of this material are defined in the <http://clock.uclan.ac.uk/policies/>

## Myocardial Deformation Imaging Meta-Analysis in Two Cohorts of Patients from UAE and Heart Hospital Hamadmedical Corporation: A Potential Role in Assessment of Coronary Artery Disease Severity and Myocardial Viability

Sherif A Baath Allah<sup>1</sup>, Mohammed Elmahal<sup>2</sup>, Mohamed H Askar<sup>3</sup>, Jaipaul Singh<sup>4</sup>, Mohamed H Khorshid<sup>5</sup>, Petras Lohana<sup>6</sup>, Jan Fedacko<sup>7</sup>, Galal E Nagib Elkilany<sup>8,9\*</sup>

<sup>1</sup>RAK Medical and Health Science University and Masafi Hospital, Masafi, UAE;

<sup>2</sup>London University, London, UK; <sup>3</sup>Critical Care Department, Alzahra Hospital, Sharjah, UAE; <sup>4</sup>School of Forensic and Applied Biology, University of Central Lancashire, Preston, UK; <sup>5</sup>Faculty of Medicine, Zagazig University, Egypt; <sup>6</sup>Internal Medicine Department, Masafi Hospital, Masafi, UAE; <sup>7</sup>Internal Medicine Department, PJ Safaric University, Kosice, Slovakia;

<sup>8</sup>Cardiovascular Departments at Tanta University, Egypt; <sup>9</sup>Al-Elaj Medical Center, Ajman, UAE

### ABSTRACT

**Introduction:** The increasing prevalence of heart failure (HF) in coronary artery disease (CAD) urgently requires the establishment of new imaging techniques for early diagnosis and also to guide treatment of patients presented with acute coronary syndromes (ACS). Conventional echocardiography (CE) and electrocardiogram (ECG) are the gold standard methods in assessing myocardial ischemia (MI) and the function of the heart in patients with coronary artery disease (CAD). The lack of ST elevation by ECG and regional wall motion abnormalities by CE in non-ST segment elevation myocardial infarction (NSTEMI) in ACS patients reflect limited sensitivity of ECG and CE in identifying patients with acute coronary occlusion (ACO) and proper assessment of myocardial viability.

**Aim of this study:** This study now evaluates the ability of strain parameters in grading the severity of CAD to detect myocardial viability in ACS through a comparative meta-analysis in two cohorts of patients living in the UAE and Qatar. The study investigates the diagnostic accuracy of left ventricular longitudinal systolic strain function (GLS) by 2D-speckle tracking echocardiography (2D-STTE), Territorial Longitudinal Strain (TLS) analysis and post systolic strain (PSS) in ACS patients admitted at the emergency departments. All the patients had acute chest pain which is highly suggestive of NSTEMI along with coronary angiography (CA).

**Methods:** The study recruited two groups, comprising of 347 patients, who were presented with acute coronary syndrome (NSTEMI) at the emergency department. The first group had 214 consecutive patients who had acute chest pain and high-risk profile and they were admitted to the emergency department at Eastern Emirates Hospitals, El-Fujairah-Dibba (EEH), UAE. The second group consisted of 133 from emergency department at Heart Hospital-Hamad Medical Corporation (HHMC), Qatar. In both groups, 85% of the patients were men with ages from 32 to 65 years (mean  $\pm$  SD: 49.4  $\pm$  9.5 years). Significant CAD was defined as having at least one epicardial vessel with  $\geq$  70% or left main  $>$ 50% stenosis. All patients enrolled in this study underwent basic echocardiography, speckle tracking analysis, and coronary angiography. In 70 patients, PSS was calculated and myocardial perfusion imaging

**Correspondence to:** Galal E Nagib Elkilany, Cardiovascular Departments at Tanta University, Egypt, E-mail:galal@kilany.org

**Received:** July 24, 2020; **Accepted:** August 07, 2020; **Published:** August 14, 2020

**Citation:** Allah BAS, Elmahal M, Askar HM, Singh J, Khorshid HM, Lohana P, et al (2020) Myocardial Deformation Imaging Meta-Analysis In Two Cohorts Of Patients From UAE And Heart Hospital-Hamad Medical Corporation: A Potential Role In Assessment Of Coronary Artery Disease Severity And Myocardial Viability. J Clin Exp Cardiol.11:659. DOI: 10. 35248/2155-9880.20. 11. 665.

**Copyright:** ©2020 Allah BAS, et al. This is an open-access article distributed under the terms of the Creative Commons Attribution License, which permits unrestricted use, distribution, and reproduction in any medium, provided the original author and source are credited.

(MPI) was utilized as gold standards for the assessment of myocardial viability in patients with documented NSTEMI/ACS. The sensitivity, specificity, positive and negative predictive values of peak longitudinal systolic strain (2D-STE) and PSS were calculated. Left ventricular systolic strain was displayed as bull's eye plot and territorial longitudinal strain (TLS) in the territory of the infarct-related artery. They were obtained within 24 hours from admission. Coronary angiography (CA) was performed within 24 hours from admission and used as a reference tests to assess the severity of CAD.

**Results:** Echocardiogram obtained from the patients showed any no wall motion abnormalities at rest, although speckle tracking analysis was abnormal in 167 patients. In the first group of patients from the UAE, GLS showed a high sensitivity of 80% and a very high specificity of 93% for detection of significant CAD. In addition, PSS demonstrated a high sensitivity of 80% with an average specificity of 57%. The combination of GLS and PSS showed a further increase in sensitivity, specificity with positive and negative predictive values of 98%, 91%, 99% and 97%, respectively. Therefore, a very high correlation of GLS and PSS with coronary angiography was demonstrated:  $r=0.90$ ,  $p<0.0001$  and  $R=0.88$ ,  $p<0.0001$ , respectively. Furthermore, PSS showed a very high concordance with MPI scan (stress-rest-reinjection studies) in detection of ischemic viable myocardium with very high sensitivity of 85%,  $r=0.79$ . In the Qatari (HHHMC) patients, a multi-vessel disease or left main disease (MV) was documented in 53.6%, and those with single vessel disease (SV) in 46.4%. LAD, circumflex and RCA lesions were found in 65, 50 and 39 patients, respectively. A control group of 129 cases was selected from outpatients referred to the echocardiography unit. The results showed that in comparison to CA, GLS sensitivity and specificity were 84% and 70%, respectively in all the patients. The sensitivity of GLS was 87% in MV and 80% in SV. Territorial strain sensitivity was 50%, 74% and 84.6% for the left anterior descending artery (LAD), circumflex and right coronary artery (RCA), respectively compared to specificity values of 64%, 65% and 61.7%, respectively.

**Conclusion:** It is concluded that GLS by speckle tracking analysis is definitely an accurate method in early diagnosis of the severity of CAD in patients presenting with NSTEMI/ACS. The combined use of GLS and PSS showed very high diagnostic accuracy for the identification of significant CAD in these patients. Strain imaging by STE may be applied to diagnose the severity of myocardial ischemia by showing reduction in peak systolic strain. Moreover, it is equally important to demonstrate post-systolic shortening which is a characteristic feature of ischemic viable myocardium after ACS requiring revascularization.

**Keywords:** Coronary artery disease; Speckle tracking echocardiography; Global longitudinal strain; Post systolic strain; Myocardial perfusion imaging; Coronary-angiography.

## INTRODUCTION

The application of speckle tracking for analysis of longitudinal strain introduces a more quantitative method for the detection of subtle myocardial alterations in CAD patients presented with ACS and further facilitate a more accurate diagnosis [1]. This may guide treatment and may also improve prognosis in these patients. However, the power of derived strain parameters to recognize high risk patients for significant coronary disease is still not completely defined and understood. Currently, there are only few studies of speckle tracking application in ACS, notably in non-ST-elevation MI. Quantification of myocardial deformation by strain echocardiography may reveal significant CAD in patients with non-ST elevation acute coronary syndrome [2]. These studies recruited either a small number of patients or did not correlate GLS values with coronary angiography results. Furthermore, previous studies in our hospital in the UAE investigated territorial strain, GLS [3] and post systolic shortening (PSS) in patients presented with ACS [4].

The present retrospective meta-analysis study was undertaken to demonstrate the sensitivity and specificity of GLS via STE and PSS in patients presenting with acute chest pain and validate a cut off values of significant CAD in both Qatar and the UAE for comparison. In addition, the study investigated the combined use of post systolic shortening (PSS) with resting global longitudinal systolic strain (GLS) in order to improve the diagnostic CAD and myocardial viability after ACS. STE-based myocardial deformation imaging can allow in quantifying myocardial function and viability far beyond what can be done with sole qualitative visual assessment by CE. This study further now explains how this technique is used in investigating patients with CAD.

## METHODS

### Hospitals

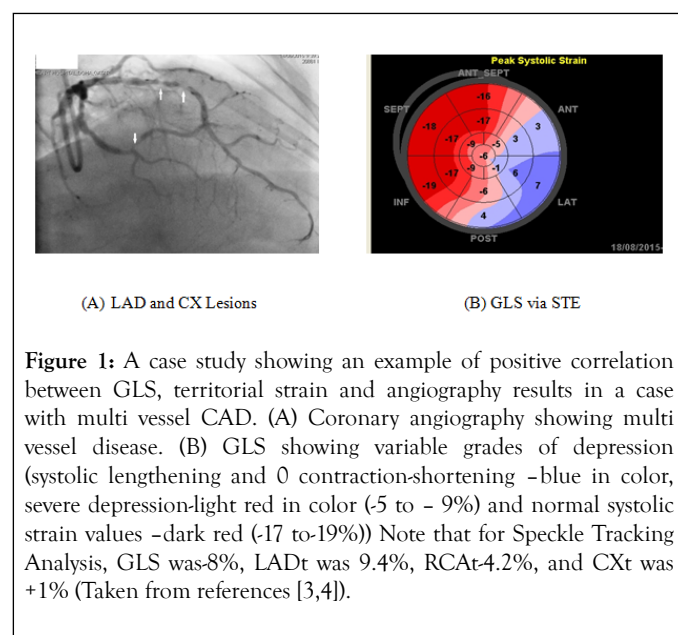
This work was conducted at the hospital critical care department of HHHMC, Doha, Qatar and at chest pain unit of Eastern Emirates Hospitals-El-Fujairah Diba (EEEH), UAE. The study had the full ethical clearance and permission from the Ethics

Committee of the HHHMC and EEEH to undertake the investigation.

### Patient population

Between the period 01/01/2014 to 31/06/2015, 1,422 patients were presented to the hospital critical care and emergency-chest pain unit departments with NSTEMI/ACS at both centers in Qatar and the UAE. Coronary angiography was performed within 24 hours following the admission of 956 (79.1%) cases at HHHMC and 70 patients at EEEH. From the 1,422 recruited patients, 1,372 of them had undertaken echocardiography prior to coronary angiography.

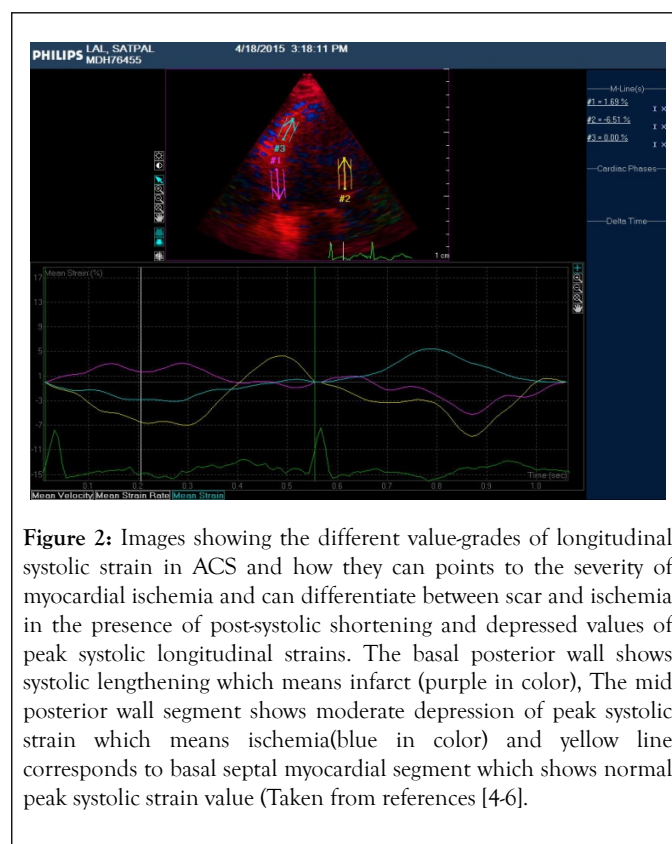
At EEEH in the UAE, 214 consecutive patients with acute chest pain and high-risk profile were admitted and 85% of the patients were male subjects with ages between 32 to 65 years (mean  $\pm$  SD:  $49.4 \pm 9.5$  years). Significant CAD was defined as having at least one epicardial vessel with  $\geq 70\%$  or left main  $>50\%$  stenosis. All patients enrolled in this study underwent basic echocardiography, speckle tracking analysis, and coronary angiography. In 70 patients, PSS and myocardial perfusion imaging (MPI), had been utilized as gold standards for the assessment of myocardial viability in patients with documented NSTEMI/ACS. The sensitivity, specificity, positive and negative predictive values of peak longitudinal systolic strain (2D-STE) and PSS were calculated. Left ventricular systolic strain was displayed as bull's eye plot and territorial longitudinal strain (TLS) in the territory of the infarct related artery was obtained within 24 hours from admission. Coronary angiography was performed within 24 hours from admission and used as a reference tests to assess the severity of CAD. Left ventricular systolic strain was displayed as bull's eye plot as shown in Figure 1 from a patient with ACS illustrating the different grades of depression in systolic shortening implying that there was some degree of subjectivity in the interpretation of strain images.



**Figure 1:** A case study showing an example of positive correlation between GLS, territorial strain and angiography results in a case with multi vessel CAD. (A) Coronary angiography showing multi vessel disease. (B) GLS showing variable grades of depression (systolic lengthening and 0 contraction-shortening -blue in color, severe depression-light red in color (-5 to -9%) and normal systolic strain values -dark red (-17 to-19%)) Note that for Speckle Tracking Analysis, GLS was -8%, LADt was 9.4%, RCA t-4.2%, and CXt was +1% (Taken from references [3,4]).

Figure 2 below displays the different values - grades of longitudinal systolic strain in NSTEMI/ACS, it can points to the

severity of myocardial ischemia and be able to differentiate between myocardial scar and viable ischemic myocardium ; PSS and mildly depressed values of GLPSS are considered important signs of severe ischemic although viable myocardium.



**Figure 2:** Images showing the different value-grades of longitudinal systolic strain in ACS and how they can points to the severity of myocardial ischemia and can differentiate between scar and ischemia in the presence of post-systolic shortening and depressed values of peak systolic longitudinal strains. The basal posterior wall shows systolic lengthening which means infarct (purple in color), The mid posterior wall segment shows moderate depression of peak systolic strain which means ischemia (blue in color) and yellow line corresponds to basal septal myocardial segment which shows normal peak systolic strain value (Taken from references [4-6]).

In the HHHMC Qatari patients, wall motion abnormalities were found in 607 (69%) cases. Of the remaining 273 (31%) cases, 140 (51.3%) were excluded for various reasons. The remaining 133 (48.7%) patients were included in the study. Figure 1 illustrated a typical case study of patient which demonstrated a positive correlation between GLS, territorial strain and angiograph results in a case typical of multi-vessel disease.

### Control group

One hundred and twenty nine (129) age-matched control subjects were referred for either echocardiography for non-cardiac or atypical symptoms with low risk for CAD and normal conventional echocardiography and GLS was used as a control group.

### Inclusion criteria

#### Sinus rhythm

Echocardiography study of adequate quality and adjusted optimum frame rates (50-80 frame per second) for offline speckle tracking analysis.

#### Evidence of nonST segment elevation acute coronary syndromes (NSTEMI/ACS)

Exclusion criteria included the following:

Age less than 25 or above 65 years.

ST-elevation myocardial infarction.

Regional wall motion abnormalities on resting study.

Previous known myocardial infarction.

Previous revascularization (percutaneous coronary intervention PCI or coronary artery bypass grafting CABG).

Significant valvular lesions (more than mild stenosis or regurgitation).

Atrial fibrillation, significant arrhythmia or left bundle branch block (LBBB).

### Technically limited studies

The criteria of diagnosis of risk factors, such as hypertension, diabetes mellitus, smoking and hyperlipidemia and obesity were based on AHA guidelines or available records of treatment. Laboratory investigations-cardiac biomarkers, electrocardiography (ECG), resting echocardiography and coronary angiography were done in all NSTEMI ACS patients. A cutoff of percent diameter stenosis  $>70\%$  for any of the three epicardial coronary arteries or  $>50\%$  for left main (LM) coronary artery was considered significant [7]. Left main was considered as a multi-vessel disease in this study. CAD patients were subdivided according to their coronary angiography results into those with left main-multi-vessel disease (MVD) and those with single vessel disease (SVD).

### Echocardiography

Standard measurements were obtained from M-mode, 2D and Doppler methods in accordance to the American Society of Echocardiography (ASE) guidelines [8]. This study also employed two-dimension STE in tackling the scientific problem. Data analysis was performed by offline analysis in all patients, as by the automated functional imaging (AFI) method provided by the ECHOPAC system. The left ventricle was divided into 17 segments, and peak systolic longitudinal strain of each segment was obtained. The case with more than 2 non-interpretable segments was excluded. The territorial longitudinal strain (TLS) was the average of the segments supplied by each artery, adapted from the ASE guidelines. Shared segments were included for both arteries,

The normal values of GLS and TLS extracted from the data analysis of the control group were  $<-18.7\%$  and  $<-16.7\%$ , respectively. On the other hand, a higher cut-off value of  $GLS <-14.5\%$  used instead in the first group-EEEH to identify patients with severe CAD.

### Statistical analysis

Data were coded and entered using the statistical package SPSS (Statistical Package for the Social Science) version 23. Data were summarized using mean and standard deviation (M+SD) in quantitative data and using frequency (count) and relative frequency (percentage) for categorical data. Comparisons between groups were done using unpaired Student's t-test when comparing 2 groups and analysis of variance (ANOVA) with

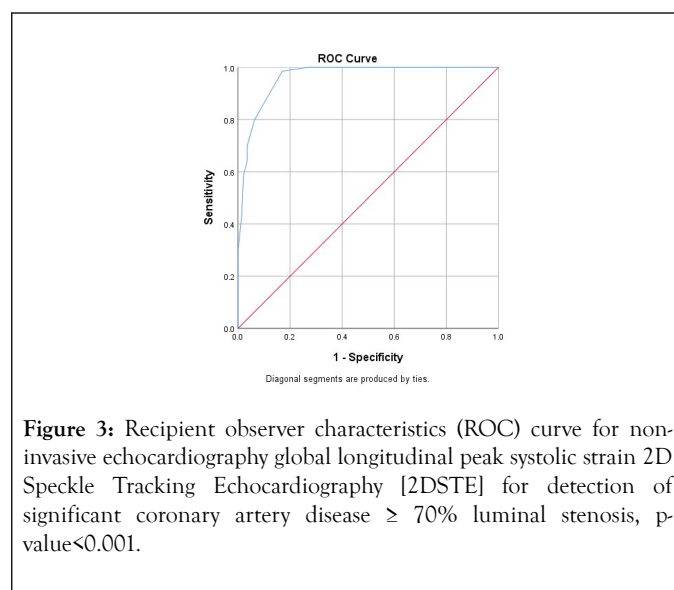
multiple comparisons post hoc test when comparing more than 2 groups [9]. For comparing categorical data, the chi-square ( $\chi^2$ ) test was performed. The exact test was used instead when the expected frequency was less than 5 [10]. Standard diagnostic indices included sensitivity and specificity [11]. The ROC curve was constructed with an area under curve analysis performed to detect the best cut-off values for detection of lesions. P-values less than 0.05 were considered to indicate statistical significance.

### RESULTS

In both groups, 85% of the patients were men with ages from 32 to 65 years (mean  $\pm$  SD:  $49.4 \pm 9.5$  years). In the UAE group, a higher cut-off value of GLS of  $<-14.5\%$  was used which could explain the significant higher sensitivity and specificity in this study for accurate detection of severe CAD.

The final population in this study group consisted of 203 patients who were diagnosed with acute retrosternal chest pain, high risk of CAD, with high index of suspicion of NSTEMI ACS (acute coronary syndrome). Global longitudinal systolic strain (GLS) by STE was feasible in 90% of patients. The clinical major risk factors for CAD were more significantly ( $p < 0.05$ ) common among the 15% female patients in comparison to the 85% male patients, except for smoking tobacco which is far more common among male population in the present study and generally in the Gulf Region as well.

In this subgroup of patients with significant CAD, the combined admission parameters (cardiac biomarkers, basal ECG and 2D-echocardiogram) showed sensitivity and specificity of 70% and 68%, respectively. Alternatively, GLS showed a high sensitivity of % and very high specificity of 93% for the detection of significant CAD. On the other hand, PSS demonstrated a high sensitivity of 80% with low specificity of 57% (Figure 3).

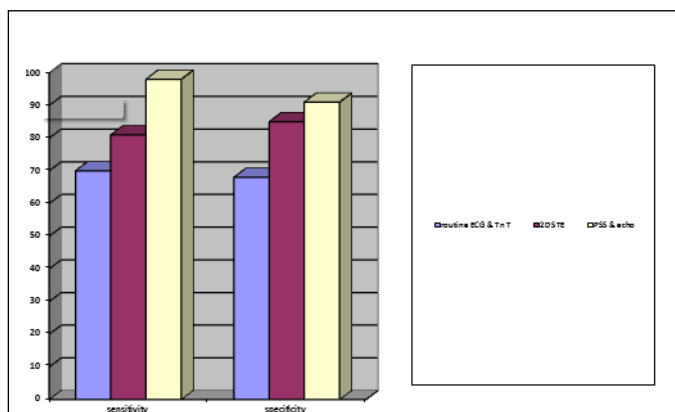


**Figure 3:** Recipient observer characteristics (ROC) curve for non-invasive echocardiography global longitudinal peak systolic strain 2D Speckle Tracking Echocardiography [2DSTE] for detection of significant coronary artery disease  $\geq 70\%$  luminal stenosis,  $p$ -value  $< 0.001$ .

Figure 4 below shows the sensitivity, specificity, negative and positive predictive value of GLS and PSS combined together were 98%, 91%, 99% and 97%, respectively. Furthermore, the combined GLS and PSS demonstrated a very high correlation



with coronary angiography ( $R=0.90$ ,  $p<0.0001$  and  $R=0.88$ ,  $p<0.0001$ , respectively).



**Figure 4:** Bar charts showing the sensitivity and specificity of routine investigations (blue colour columns) performed for diagnosis of acute coronary syndromes (CAD critical stenosis  $\geq 70\%$  (ECG, WMSI echocardiography and cardiac biomarkers) versus 2 dimensional echocardiography global longitudinal peak systolic strain STE (pink color columns) and systolic strain new criteria (yellow color columns). The combined usage of PSS and 2D longitudinal systolic strain STE improved the sensitivity and specificity of critical CAD significantly ( $p<0.0001$ ).

In the HHHMC group 133 patients were included and this was based on their coronary angiography results. Patients were further divided into two sub-groups, consisting of 97 patients with significant CAD (mean age  $50.15 \pm 6.99$  years, 90 (92.8%) males, 7 (6.2%) females) and 36 (mean age  $48.39 \pm 11.98$  years, 23 (63.9%) males and 13 (36.1%) females without CAD.

The CAD lesions were documented by CA in the significant groups, especially those with left main or multi-vessel disease (MVD);  $n=52$  (53.6%), and patients with single-vessel disease (SVD);  $n=45$  (46.4%). LAD, circumflex and RCA lesions were found in 65, 50, and 39 patients, respectively (Table 1).

**Table 1:** Table showing comparison of the different risk factors, cardiac biomarkers, the mean renal function test and the ECG among the different groups (significant CAD, non-significant CAD and the control group). Note that the data were obtained from admission files of patients recruited for this study from the HHHMC. Data are expressed as mean  $\pm$ SD with p values (\* $p<0.01$ ).

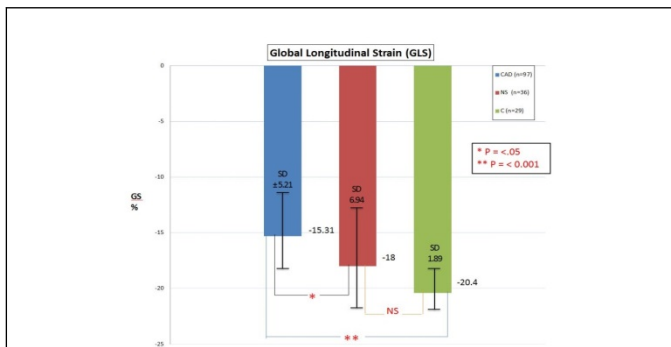
Risk Factors		CAD (n=97)	Group NS (n=36)		Group C (n=29)		p Value
		Number	%	Number	%	Number	
Cardiac biomarkers	POS	89	91.8 %	20	55.6 %	---	<0.001*
	NEG	8	8.2 %	16	44.4 %	---	

Known hypertension	NEG	38	39.2 %	20	55.6 %	23	79.3 %	<0.001*
	POS	59	60.8 %	16	44.4 %	6	20.7 %	
Known diabetes mellitus	NEG	49	50.5 %	23	63.9 %	23	79.3 %	0.013*
	POS	48	49.5 %	13	36.1 %	6	20.7 %	
Current smoker	NEG	46	47.4 %	23	63.9 %	24	82.8 %	0.002*
	POS	51	52.6 %	13	36.1 %	5	17.2 %	
Known hyperlipidemia	NEG	55	56.7 %	25	69.4 %	26	89.7 %	0.002*
	POS	42	43.3 %	11	30.6 %	3	10.3 %	
ECG (LA D)	Positive	21	24.4 %	7	23.3 %	0	.0 %	0.004*
	Negative	65	75.6 %	23	76.7 %	28	100.0 %	
ECG (RC A)	Positive	17	19.3 %	8	26.7 %	0	.0 %	0.004*
	Negative	71	80.7 %	22	73.3 %	28	100.0 %	
ECG (Cx)	Positive	21	23.9 %	2	6.7 %	0	.0 %	0.008*
	Negative	67	76.1 %	28	93.3 %	28	100.0 %	
Cardiac troponins	Mean $\pm$ SD	523.12	694.34	173.65	347.54	.	.	0.005*
Urea	Mean $\pm$ SD	5.49	4.55	4.87	1.97	5.41	2.89	0.707
Creatinine	Mean $\pm$ SD	89.81	30.72	84.58	21.40	68.58	21.71	0.003*

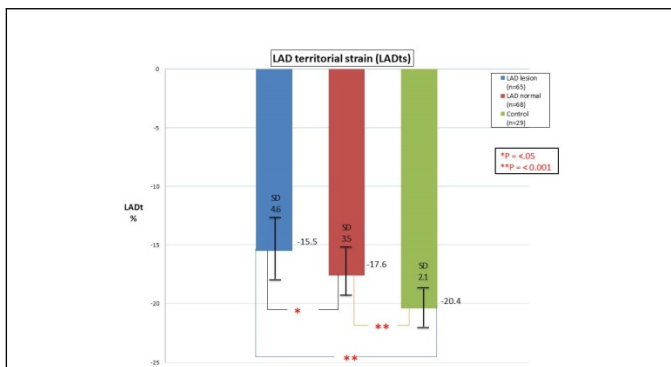
### Speckle tracking analysis

Global (GLS) and territorial strain analyses were performed in all individuals. GLS was compared between the 3 groups (see Figure 5). LAD territorial strain (LADts) was compared between those with LAD lesions and others with NSTEMI/ACS versus the control group (see Figure 6). Similarly, RCA territorial strain (RCAts) was compared between those with RCA lesions, other vessel disease and the control group as well (see Figure 7) and

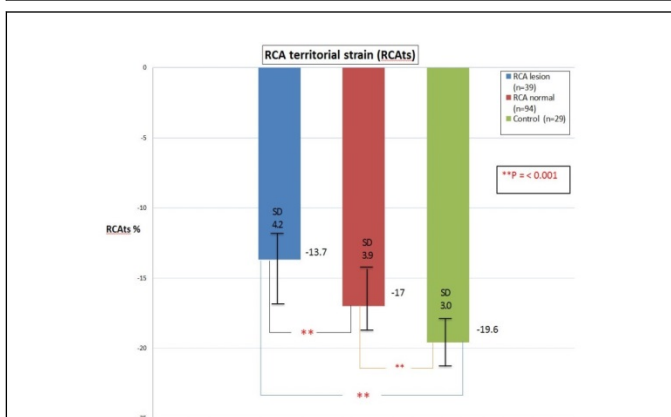
finally, territorial strain was compared between those patients with circumflex artery lesions (CXts), other CAD patients and the control group ( see Figure 8).



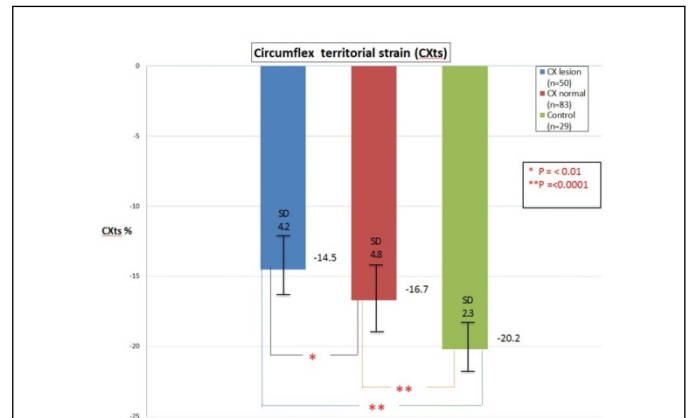
**Figure 5:** Mean value for global longitudinal strain (GLS) in the different groups. CAD=patients with significant coronary artery disease, NS=patients with non-significant lesions or with normal coronary angiograms, C=control group.



**Figure 6:** Territorial longitudinal strain in area supplied by LAD (LADt) showing mean value and statistical significance in different groups; LAD lesion=patients with significant coronary artery disease in LAD territory, LAD normal=patients with non-significant LAD lesions or with normal LAD, C=control group.



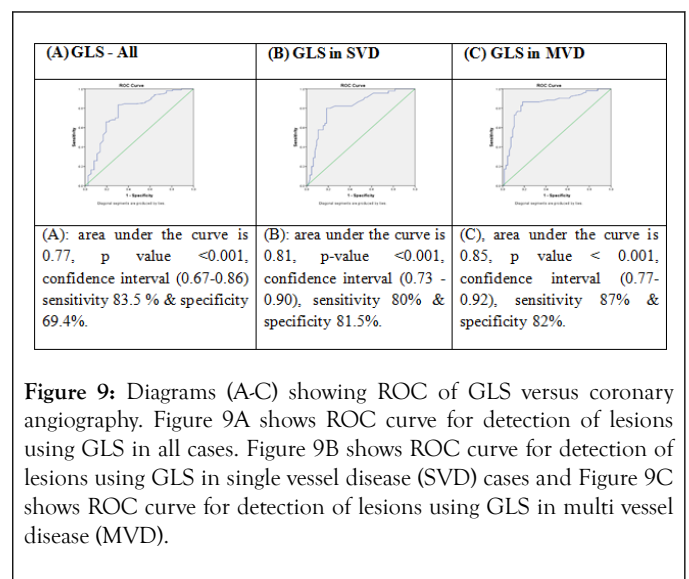
**Figure 7:** Territorial longitudinal strain in area supplied by RCA (RCAt) showing mean value and statistical significance in different groups; RCA lesion=patients with significant coronary artery disease in RCA territory, RCA normal=patients with non-significant RCA lesions or with normal RCA, C=control group.



**Figure 8:** Territorial longitudinal strain in area supplied by CX (CXt) showing mean value and statistical significance in different groups; CX lesion=patients with significant coronary artery disease in CX territory, CX normal=patients with non-significant CX lesions or with normal CX, C=control group.

#### MAJOR FINDINGS OF THIS STUDY FROM THE UAE AND HHHMC, QATAR

Global longitudinal strain was significantly lower in the control group ( $-20.4 \pm 2.7\%$ ), compared to CAD ( $-15 \pm 0.5\%$ ),  $p < 0.001$ . It was also lower in patients with non-significant CAD, compared to those with CAD ( $p < 0.05$ ); (see Figure 9).

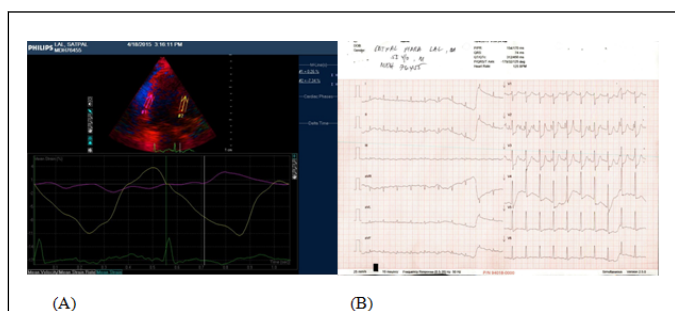


**Figure 9:** Diagrams (A-C) showing ROC of GLS versus coronary angiography. Figure 9A shows ROC curve for detection of lesions using GLS in all cases. Figure 9B shows ROC curve for detection of lesions using GLS in single vessel disease (SVD) cases and Figure 9C shows ROC curve for detection of lesions using GLS in multi vessel disease (MVD).

The results also show that the territorial strain of the left anterior descending coronary artery (LAD) was significantly ( $p < 0.05$ ) higher compared to the same regions in those with non-significant LAD lesions ( $-17.6 \pm 3.5\%$ ) and the control group ( $-20 \pm 2.1\%$ ). In contrast, territorial strain values were ( $-13.7 \pm 4.2\%$ ) in severe right coronary artery (RCA) disease which was significantly higher ( $p < 0.05$ ) compared to those with non-significant RCA lesions ( $-17.6 \pm 3.9\%$ ) and also with the control group ( $-19.6 \pm 3\%$ ). Finally, territorial strain of the left circumflex artery (CXt) was also associated with significant ( $P < 0.05$ ) lesions in 50 patients. Typically, CXt in those patients was  $-14.5 \pm 4.2\%$  which was significantly higher ( $P < 0.05$ )

compared to those with non-significant CXt lesions (-16.7±4.8%) or to the control group (-20.2±2.3%). Interestingly, the present study demonstrated that post systolic shortening (PSS) has the strongest correlation with MPI ( $p<.001$ ) in prediction of viable-ischemic myocardium in critically severe CAD in NSTEMI ACS patients (see Figures 2 and 10).

The results from these comparative studies from the UAE and Qatar have clearly demonstrated an important finding when applied both GLS and PSS for critical CAD diagnosis. These data showed a further increase in sensitivity, specificity, positive and negative predictive values of 98%, 91%, 99% and 97%, respectively. Therefore, a very high correlation of combined use of GLS and PSS with coronary angiography was demonstrated with  $R=0.90$ ,  $p<0.0001$  and  $R=0.88$ ,  $p<0.0001$ , respectively); (see Figures 3 and 4).



**Figure 10:** The displays in Figure 10A shows Depressed Peak Systolic Strain of posterior and lateral wall of the left ventricle in acute posterior wall myocardial infarction which can be demonstrated clearly. Original traces 1 Figure 10B show resting EKG with ST segment depression in v1 and v3 anterior chest leads with tall R wave; (Taken from references [4,6]).

## DISCUSSION

This multicenter trial in the UAE and HHHMC-Qatar revealed cut off values of -14.5% for GLS and -9% for TLS could predict severe CAD in STEACS patients with high sensitivity and specificity. Furthermore, PSS showed the strongest correlation with MPI ( $p<.001$ ) to predict critical severe CAD and viable myocardium in ACS patients. Whether a patient has ischemia or infarct (scar), the finding of typical strain is a feature of ischemia in more than just a single segment highlighting favors of ischemic dysfunction rather than noise artifacts [12,13].

In many previous studies, GLS was shown to be an independent predictor of severe CAD both at rest and during dobutamine-induced stress echocardiography [14,15]. Another promising application of strain imaging is the identification of the relatively large subgroup of non-ST-elevation myocardial infarction in ACS patients with total coronary occlusion. As such, these patients need urgent revascularization [16]. Lack of ST elevation in these patients reflects limited sensitivity of ECG in identifying patients with acute coronary occlusion [17].

Furthermore, several studies demonstrated that patients with either preserved or mildly reduced left ventricular ejection fraction (LVEF=40-50%) after myocardial infarction had absolute GLS (<14%) and with increased risk for the combined endpoint of all-causes of mortality and heart failure admission

[18]. These findings show concordant results with the present study [4,5].

In the present study, PSS has been proposed as a marker of viability, but should not be used alone as an index of viability, since post-systolic shortening also occurs in post infarct scarred myocardium (necrosis) and in cardiomyopathy [46].

In the acute phase of ST-elevation myocardial infarction (STEMI), viability imaging techniques by MPI and cardiac magnetic resonance imaging (CMR), are generally not validated and/or not recommended. Accordingly, several small studies should be aimed to evaluate the ability of strain parameters assessed in the acute phase of ST-elevation myocardial infarction (STEMI) in order to predict myocardial viability after ACS and revascularization.

A previous study [19] which included Thirty-one STEMI patients whose coronary artery was re-canalized and in whom baseline echocardiogram showed regional wall motion abnormalities in the form of akinesia in the infarcted area. Two dimensional left ventricular GLS and TLS in the territory of the infarct related-artery were obtained within 24 hours from admission. Delayed enhancement CMR was used as a reference test to assess post-revascularization myocardial viability. Delayed-CMR was performed 3 months after percutaneous coronary intervention. The study revealed that GLS was correlated with delayed CMR ( $=0.54$ ,  $p=.002$ ) and a cut off value of -13.9% for GLS predicted viability with 86% sensitivity and 78% specificity. TLS showed the strongest correlation with CMR ( $=0.69$ ,  $p<.001$ ). A cut off value of -9.4% for TLS yielded a sensitivity of 78% and a very high specificity of 95% to predict myocardial viability. The investigators concluded that GLS and TLS measured in the acute phase of STEMI can definitely predict myocardial viability after acute myocardial infarction. Moreover, they suggested that these techniques can be used as prognostic indicators to guide the usefulness of revascularization in these patients. These findings are in concordant to the present study which used PSS as an additional parameter to GLS and TLS. Moreover, MPI was utilized as a gold standard instead of cardiac CMR in the present study.

Both tissue Doppler Imaging (TDI) and STE have been shown to be facilitative in prediction of myocardial viability. Moreover, many limitations of qualitative assessment of LV myocardial wall thickness and regional wall motion abnormalities are operator-dependent with CE and during stress echocardiography (STE). Bansal and colleagues [20] revealed that GLS and circumferential strain (CS) and strain rate (SR) measurements at rest and low-dose DSE were predictive of functional recovery post revascularization using strain-based imaging. Furthermore, only tissue velocity imaging was found to have incremental value over wall motion analysis.

Based on a study by Hoffmann et al. [21], an increase of peak strain rate greater than or equal to 0.23/s had a sensitivity of 83% and specificity of 84% in discerning viable myocardium as determined by 18FDG. Similar to the present study, Ran and colleagues [22] demonstrated a change in GLS (>-14.6%) which provided a sensitivity of 86.7% and specificity of 90.2% in the



detection of viable myocardium, using strain imaging with adenosine STE.

Recent studies have provided new insights into the value of layer-specific 2DSTE for evaluating viable myocardium in patients with ACS. They also make a comparison with dual isotope simultaneous acquisition single photon emission computed tomography (SPECT). It is concluded that the GLS and PSS analysis of 2D STE can evaluate the viable myocardium well at high index of diagnostic accuracy, sensitivity and specificity. More so, they are similar to those of SPECT, resulting in GLS via 2D-STE being a good option for the assessment of viable myocardium [4,23]. Furthermore, resting and post-dobutamine-induced stress STE strain and strain rate parameters can assess the viability in akinetic segments when compared to 18FDG-PET imaging in acute MI [24].

The importance of early and accurate diagnosis of non-ST-segment acute myocardial infarction (NSTEMI ACS) and unstable angina is now evident with the introduction and proven efficacy of early invasive revascularization strategies. Many studies have demonstrated the ability of STE to detect changes in strain patterns during ST elevation myocardial infarction (STEMI), but its accuracy to detect mild changes during unstable angina (UA) and non-ST elevation MI is currently unclear.

The results of the present multicenter study from the UAE and Qatar \*( HHHMC) showed that average GLS sensitivity and

specificity were 82% and 80%, respectively in all patients presented with ACS. Importantly, the sensitivity was 87% in extensive CAD and 80% in single vessel disease. On the other hand, territorial strain sensitivity was 50%, 74% and 84.6% for LAD, circumflex and RCA, respectively. Corresponding specificity was 64%, 65% and 61.7%, respectively [25-36].

## CONCLUSION

The present study also shows a general agreement with many previously published data. However, it differs in three ways from the previous studies and they included: (i) larger number of cases investigated, (ii) several 2DE and STE parameters used (GLS, PSS, TLS), (iii) coronary angiography and MPI used as a gold standard and (iv) examining the territorial strain accuracy in the localization of significant coronary lesions. Interestingly, PSS has been proposed as a marker of viability in the present study, but should not be used alone as an index of viability, since post-systolic shortening also occurs in post infarct scarred myocardium (necrosis) and in different forms of hypertrophic and dilated cardiomyopathy.

Table 2 summarizes the major findings from other major studies and their differences compared to the current study. A meta-analysis review of different studies published in the last 5 years was collected and assessed carefully. The data show the average accuracy of GLS by STE to predict significant CAD in ACS.

**Table 2:** The data in table show a review of different studies published in 2DE and STE in the diagnosis of CAD in ACS.

Studies	Numbers	Modality	WMA or Low LVEF	Cut Off Level	Sensitivity and Specificity	Gold Standard	TLS
Alireza et al., 2015	119	VVI technology	Excluded	GLS-16%	GLS 77% and 63%	CA	No
Sebastian et al., 2013	77	Toshiba	Included	TLS-14% GCS-19.2%	Sub endocardial TLS 89% and 81%.		Yes
Jornar et al., 2010	111	GE	Not mentioned	TCS-10%. GLS-14%	TCS-10% have 90% sensitivity and 88% TLS-14.0% SEN 76% SPECIFICITY 66%.	MRI	Yes
Christian Eek et al, 2010 and Jornar et al, 2010	150 patients	GE	Included	GLS-16.3%	67% and 71%	CA	No
Christian-Eek et al., 2010	150	GE	Included	GLS-14%	85% and 70%	CA	No
Jin-Oh Choi et al., 2009	108	GE	Excluded	GLS-17.9%	79% and 79%	CA	No

## SOME LIMITATIONS OF THIS STUDY

### The present study has several limitations and they included the following:

It was difficult to find an appropriate control group with low risk for coronary artery disease.

All patients in this study were selected for coronary angiography, which made them have a higher likelihood of coronary artery disease. In turn, this might have affected specificity and sensitivity.

Presenting normal reference values for different myocardial segments is still problematic as they depend on patients' demographics, modality used and methodology.

(d) Post systolic strain-shortening (PSS) is not specific for CAD and can be seen in other cardiovascular diseases as hypertrophic cardiomyopathy and dilated cardiomyopathy.

## ACKNOWLEDGEMENT

To Prof. Dr. Alia Abdelfattah, MD and Dr. Sherifhelmy, MD at critical care department at Cairo University, Kasr El-Aini University Hospital, Cairo, Egypt for their meticulous supervision of data collection and revision of sub-group 2 studied patients; and to Dr. Abdulla Alhajiri, MD chairman of interventional cardiology department at ElFujairah Hospital, UAE for his valuable contribution as interventional cardiologist in sub-group 1 of UAE patients.

## REFERENCE

Leitman M, Lysiansky M, Lysyansky P, Friedman Z, Tyomkin V, Fuchs T, et al. Circumferential and longitudinal strain in 3 myocardial layers in normal subjects and in patients with regional left ventricular dysfunction. *J Am Soc Echocardiography*. 2010; 23: 64-70.

Sarvari SI, Haugaa KH, Zahid W, Bendz B, Aakhus S, Aaberge L, et al. Layer-specific quantification of myocardial deformation by strain echocardiography may reveal significant coronary artery disease in patients with non-ST elevation acute coronary syndrome. *JACC Cardiovasc Imaging*. 2013; 6: 535-544.

Helmy S, Askar M, Galal E, Nagib E, Singh J, Arafa S, et al. Diagnostic Value of Speckle Tracking Strain Analysis in Non-ST Elevation Acute Coronary Syndromes; Comparison study with Coronary Angiography. *World Heart J*. 2018; 10 1; 57-71.

El-Kilany GE, Sozzi, FAB, Gherbesi. Diagnostic value of speckle-tracking 2d-echocardiogram in patients with acute chest pain and high risk of coronary artery disease. *ESC Preventive Cardiology*, (EUD ID: 53324).

Elkilany N, G E, Singh RB, Hristova K. Cardiovascular Imaging for Investigation of Cardiovascular Diseases. *EC Cardiology*. 2019; 6 2: 163-166.

Singh RB, Elkilany G, Fedacko J. Viewpoint: Utility and Necessity of Cardiovascular Imaging in a Chest Pain Unit. *World Heart Journal*. 2016; 8 2: 125-131.

Eagle KA, Guyton RA, Davidoff R, Edwards FH, Ewy GA, Gardner TJ, et al. American College of Cardiology/American Heart Association Task Force on Practice Guidelines Committee to Update the 1999 Guidelines for Coronary Artery Bypass Graft Surgery; American Society for Thoracic Surgery; Society of Thoracic Surgeons. ACC/AHA 2004 guideline update for coronary artery bypass graft surgery: summary article. A report of the American College of Cardiology/American Heart Association Task Force on Practice Guidelines (Committee to Update the 1999 Guidelines for Coronary Artery Bypass Graft Surgery). *J Am Coll Cardiology*. 2005; 45 8: 1146-1154.

Lang RM, Bierig M, Devereux RB, Flachskampf FA, Foster E, Pellikka PA, et al. Recommendations for chamber quantification: a report from the American Society of Echocardiography's Guidelines and Standards Committee and the Chamber Quantification Writing Group, developed in conjunction with the European Association of Echocardiography, a branch of the European Society of Cardiology. *J Am Soc Echocardiography*. 2005; 18: 1440-1463.

Chan YH. Biostatistics 102: Quantitative Data – Parametric and Non-parametric tests. *Singapore Med J*. 2003; 44 8: 391-396.

Chan YH. Biostatistics 103: Qualitative Data – Tests of Independence. *Singapore Med J*. 2003; 44 10: 498-503.

Galen RS. Predictive values and efficiency of laboratory testings. *Pediat J. Clin North Am*. 1980; 27: 861-869.

Edvardsen T, Aakhus S, Endresen K, Bjornerheim R, Smiseth OA, Ihlen H. Acute regional myocardial ischemia identified by 2-dimensional multi region tissue Doppler imaging technique. *J Am Soc Echocardiogr*. 2000; 13:986-994.

Kukulski T, Jamal F, Herbots L, D'hooge J, Bijmens B, Hatle L, et al. Identification of acutely ischemic myocardium using ultrasonic strain measurements. A clinical study in patients undergoing coronary angioplasty. *J Am Coll Cardiol*. 2003; 41; 810-819.

Biering-Sorensen T, Hoffmann S, Mogelvang R. Myocardial strain analysis by 2-dimensional speckle tracking echocardiography improves diagnostics of coronary artery stenosis in-stable angina pectoris. *Circ Cardiovasc Imaging*. 2014; 7: 58-65.

Voigt JU, Exner B, Schmiedehausen K, Huchzermeyer C, Reulbach U, Nixdorff U, et al. Strain-rate imaging during dobutamine stress echocardiography provides objective evidence of inducible ischemia. *Circulation*. 2003; 107:2120-2126.

Eek C, Grenne B, Brunvand H, Aakhus S, Endresen K, Hol PK, et al. Strain echocardiography and wall motion score index predicts final infarct size in patients with non-ST-segment-elevation myocardial infarction. *Circ Cardiovasc Imaging*. 2010; 3:187-194.

Grenne B, Eek C, Sjøli B, Dahlslett T, Uchto M, Hol PK, et al. Acute coronary occlusion in non-ST-elevation acute coronary syndrome: outcome and early identification by strain echocardiography. *Heart*. 2010; 96:1550-1556.

- Ersboll M, Valeur N, Mogensen UM, Andersen MJ, Møller JE, Velazquez EJ, et al. Prediction of all-cause mortality and heart failure admissions from global left ventricular longitudinal strain in patients with acute myocardial infarction and preserved left ventricular ejection fraction. *J Am CollCardiol*. 2013; 61:2365–2373.
- Fathia Z, Selim B, Sofiane H, Henda N, Manel B H, Bassem R, et al. Diagnostic accuracy of strain imaging in predicting myocardial viability after an ST-elevation myocardial infarction. 2020; 99 19:1-7.
- Bansal M, Jeffriess R, Leano. Assessment of myocardial viability at dobutamine echocardiography by deformation analysis using tissue velocity and speckle-tracking. *JACC: Cardiovascular Imaging*. 2010; 3 2: 121–131.
- Hoffmann R, Altiok E, Nowak B. Strain rate measurement by doppler echocardiography allows improved assessment of myocardial viability inpatients with depressed left ventricular function. *J American College of Cardiology*. 2002; 39 (3) 443–449.
- Ran H, Zhang PY, Fang LL, Ma XW, Wu WF, Feng WF. Clinic value of two-dimensional speckle tracking combined with adenosine stress echocardiography for assessment of myocardial viability. *Echocardiography*. 2012; 29 6: 688–694.
- Liu K, Wang Y, Hao Q, Li G, Chen P, Li D. Evaluation of myocardial viability in patients with acute myocardial infarction Layer-specific analysis of 2-dimensional speckle tracking echocardiography. *Medicine*. 2019; 98 3:1-11.
- Ambudhar S, Ashwani S, Bhagwant S. Assessment of myocardial viability using echocardiographic strain imaging in patients with ST-elevation myocardial infarction: comparison with cardiac PET imaging. *J Echocardiography*. 2020; 44 23:43-54.
- Belghitia H, Brette S, Lafitte S, Reant P, Picard F, Serri K, et al. Automatic Function imaging: A new operator-independent strain method for assessing Left ventricular function. *Arch Cardiovasc Dis*. 2008; 101: 163-169.
- Eek C, Grenne B, Brunvand H, Aakhus S, Endresen K, Hol PK et al. Strain echocardiography and wall motion score index predicts final infarct size in patients with non-ST-segment-elevation myocardial infarction. *CircCardiovasc Imaging*. 2010; 3: 187-194.
- Grenne B, Eek C, Sjøli B, Dahlslett T, Brunvand H, Aakhus S, et al. Acute coronary occlusion in non-ST-elevation acute coronary syndrome: outcome and early identification by strain echocardiography. *Heart*. 2010; 96: 1550-1556.
- Ryczek R, Krzesinski P, Krzywicki P. A Two-dimensional longitudinal strain for the assessment of the left ventricular systolic function as compared with conventional echocardiographic methods in patients with acute coronary syndromes. *KardiologiaPolska*. 2011; 69: 357-362.
- Shimoni S, Gendelman G, Ayzenberg O, Smirin N, Lysyansky P, Edri O et al. Differential effects of coronary artery stenosis on myocardial function: the value of myocardial strain analysis for the detection of coronary artery disease. *J Am Soc Echocardiography*. 2011; 24 7: 748-757.
- Anwar AM. Global and segmental myocardial deformation by 2D speckle tracking compared to visual assessment. *World J Cardiol*. 2011; 4 12: 341-346.
- Sarvari SI, Haugaa KH, Edvardsen T. Layer-specific quantification of myocardial deformation by strain echocardiography may reveal significant CAD in patients with non-ST-segment elevation acute coronary syndrome. *JACC: Cardiovascular Imaging*. 2013; 6: 535-544.
- Dahlslett T, Karlsen S, Grenne B, Eek C, Sjøli B, Skulstad H, et al. Early assessment of strain echocardiography can accurately exclude significant coronary artery stenosis in suspected non-ST-segment elevation acute coronary syndrome. *J Am Soc Echocardiography*. 2014; 27 (5): 512–519.
- Loutfi M, Ashour S, El-Sharkawy E, El-Fawal S, El-Touny K. Identification of high-risk patients with non-ST segment elevation myocardial infarction using strain Doppler echocardiography: correlation with cardiac magnetic resonance imaging. *Clin. Med. Insights: Cardiol*. 2016; 10: 51–59.
- Choi JO, Cho SW, Song YB, Cho SJ, Song BG, Lee SC et al. Longitudinal 2D strain at rest predicts the presence of left main and three vessel coronary artery disease in patients without regional wall motion abnormality. *Europ J Echocardiography*. 2009; 10: 695–701.
- Norum IB, Ruddox V, Edvardsen T, Otterstad JE. Diagnostic accuracy of left ventricular longitudinal function by speckle tracking echocardiography to predict significant coronary artery stenosis. *BMC Medical Imag*. 2015; 15: 1471-2342.
- Elkilany GN, Allah S, Nanda N C, Jan F, Singh J, Mai S, et al. Hypertensive Cardiomyopathy: Diagnostic Approach and Clinical Differentiation from Hypertrophic Cardiomyopathy. *J Cardiol and Cardiovasc Ther*. 2019; 15 4: 1-8.