

Central Lancashire Online Knowledge (CLoK)

Title	The influence of surgical approach on outcomes of total hip arthroplasty
Type	Article
URL	https://clock.uclan.ac.uk/28266/
DOI	https://doi.org/10.1016/j.mporth.2016.05.006
Date	2016
Citation	Tadross, TSF, Lunn, DE, Redmond, AC and Chapman, Graham (2016) The influence of surgical approach on outcomes of total hip arthroplasty. Orthopaedics and Trauma, 30 (3). pp. 247-253. ISSN 1877-1327
Creators	Tadross, TSF, Lunn, DE, Redmond, AC and Chapman, Graham

It is advisable to refer to the publisher's version if you intend to cite from the work.
<https://doi.org/10.1016/j.mporth.2016.05.006>

For information about Research at UCLan please go to <http://www.uclan.ac.uk/research/>

All outputs in CLoK are protected by Intellectual Property Rights law, including Copyright law. Copyright, IPR and Moral Rights for the works on this site are retained by the individual authors and/or other copyright owners. Terms and conditions for use of this material are defined in the <http://clock.uclan.ac.uk/policies/>

NO CONFLICT OF INTEREST

The Influence of Surgical Approach on Outcomes of Total Hip Arthroplasty

Daniel TSF Tadross. Research Student.

NIHR Leeds Musculoskeletal Biomedical Research Unit, Leeds Teaching Hospital NHS Trust

Leeds Institute of Rheumatic and Musculoskeletal Medicine

The University of Leeds

Chapel Allerton Hospital, Leeds LS7 4SA, UK

E: um12d2t@leeds.ac.uk

Dr David E Lunn. PhD. Research Fellow

NIHR Leeds Musculoskeletal Biomedical Research Unit, Leeds Teaching Hospital NHS Trust

Leeds Institute of Rheumatic and Musculoskeletal Medicine

The University of Leeds

Chapel Allerton Hospital, Leeds LS7 4SA, UK

E: d.lunn@leeds.ac.uk

Dr Anthony C. Redmond. PhD. Head of Section of Clinical Biomechanics and Physical Medicine.

NIHR Leeds Musculoskeletal Biomedical Research Unit, Leeds Teaching Hospital NHS Trust

Leeds Institute of Rheumatic and Musculoskeletal Medicine

The University of Leeds

Chapel Allerton Hospital, Leeds LS7 4SA, UK

E: a.redmond@leeds.ac.uk

Dr Graham J Chapman. PhD. Research Fellow*

NIHR Leeds Musculoskeletal Biomedical Research Unit, Leeds Teaching Hospital NHS Trust

Leeds Institute of Rheumatic and Musculoskeletal Medicine

The University of Leeds

Chapel Allerton Hospital, Leeds LS7 4SA, UK

E: g.j.chapman@leeds.ac.uk

* corresponding author

ABSTRACT

The vast majority of total hip arthroplasties performed in the UK are undertaken using either a posterior or direct lateral approach. This review describes the functional outcomes of these approaches. Functional outcome can be assessed through motion capture of function, strength testing of muscle groups around the hip and imaging of anatomical structures. Regardless of surgical approach, total hip arthroplasty patients rarely return to the 'normal' gait exhibited by healthy age-matched controls. The direct lateral approach is associated with abductor deficiencies whilst the posterior approach may introduce extension and rotation deficits. How long functional differences persist between surgical approaches is unclear. The emergence of improved imaging technologies as well as isokinetic dynamometry (muscle strength testing) and 3D biomechanical modelling provide more comprehensive evaluations than traditional post-operative assessments such as radiology or couch examination. Targeted physiotherapy has been suggested as a possible intervention to counter lasting functional deficits. This review provides a foundation to inform surgeons of the impact of each approach to justify their surgical practice and may inform physical rehabilitation regimens post-surgery.

Key words: Educational review, total hip arthroplasty, posterior approach, direct lateral approach, functional outcome

INTRODUCTION

Total hip arthroplasty (THA) is the gold-standard treatment for symptomatic hip OA and relieves patients of the burden of daily pain and immobility. Despite the success of THA, there remains no consensus on which surgical approach produces superior functional outcomes¹. To date, few studies have measured outcomes based on surgical approach, which is thought to potentially influence post-operative function in the hip joint². As a result, surgeons generally adopt the techniques they were trained in and justifications for practice are grounded in anecdotal experience rather than following an evidence-based approach.

In the UK, 96% of THAs performed in 2014 were reported as utilising either the posterior or direct lateral surgical approach³. Other approaches prominent in the literature are the muscle-sparing direct anterior approach (DAA) and anterolateral approach, which is known to disrupt the abductor compartment. This educational review focuses on the surgical advantages and disadvantages of the posterior and direct lateral approaches to THA, in addition to identifying the effects of these surgical approaches on global function describing post-operative gait and activities of daily living (ADLs), local function describing muscle strength around the hip and iatrogenic damage of soft tissue hip structures.

SURGICAL APPROACHES

Posterior approach

The posterior approach (PA), pioneered by Moore in 1957⁴ is the main approach used in the UK and USA^{3,5}. The patient lies in a lateral decubitus position and a 10-15cm curved incision is made, starting posterior to the greater trochanter running down the shaft of the femur. An incision is made in the tensor fascia latae (TFL) in order to expose gluteus maximus which is split (Figure 1); cauterising blood vessels as the muscle is disrupted. Having retracted the gluteus maximus, the short external rotators are identified and tagged for repair and then tenotomised from their insertion at the greater trochanter revealing the posterior capsule which is incised to reveal the femoral neck and head. The operative leg is internally rotated in order to dislocate the head and a femoral neck osteotomy is performed with retractors in place to aid acetabular exposure. The leg is flexed and adducted to improve exposure of the proximal femur; once adequate exposure is achieved the implant is prepared then inserted and the external rotators are repaired.

The main advantage of the PA is that as an extensile exposure it provides increased access to the femoral shaft, aiding the surgeon in complicated cases and revisions. Uncemented and cemented fixation of the implant are possible allowing the surgeon the option to change between them intraoperatively; making the procedure less challenging for surgeons and improving their confidence in producing successful outcomes.

It is well documented that the PA is associated with a higher dislocation rate compared to other approaches⁶. It has been suggested however that where additional hip capsule repair is performed the rate is reduced^{7,8}. Patients are often assigned hip precautions, limiting their post-operative activities in order to avoid dislocation after surgery and the PA has been associated with slower recovery rates⁹. The sciatic nerve is also liable to iatrogenic nerve damage in PA THA with only 36% of patients fully recovering if the sciatic nerve is damaged¹⁰.

-----*(Figure 1 here)*-----

Direct Lateral (Modified Hardinge)

The patient is in the lateral decubitus position with an incision made over the greater trochanter extending 10 cm proximally and distally. The TFL and iliotibial band are incised and a retractor used to hold the fascia in place. On identification of gluteus medius and minimus, they are split running up to the vastus ridge at which point the joint capsule is also cut. This division is made in an M-shape to aid realignment of tissue for suture repair after implant placement (Figure 2). The femoral head is dislocated by externally rotating and flexing the hip and a femoral neck osteotomy is performed. The acetabulum is prepared with gaugers and reamers down to bleeding bone to which cement is applied and the cup inserted.

A major advantage of the direct lateral approach is that the posterior soft tissues of the hip are spared whilst the preserved attachment of gluteus medius to the femur is thought to maintain stability. The dislocation rate for direct lateral THA is almost negligible; rates of approximately 0.4% have been reported^{11,12}. Superior gluteal nerve damage is evident four weeks following direct lateral THA; however this often resolves spontaneously¹³.

-----*(Figure 2 here)*-----

SURGICAL OUTCOMES

Various measures can be used to assess hip function; some of these outcomes present an overall assessment of hip function whilst others are more specific and thus have value in explaining the capacity of the hip to fulfil local tasks. Objectively, global function encompasses the hip joint as part of the whole body as it fulfils its main purpose in locomotion. The local function of the hip concerns the strength of major muscle groups and ranges of motion (ROM); which are indicative of the health of tissues around the implant. The implant can also be assessed by its positioning in situ, along with the structure of the soft tissue components surrounding the implant. Structural assessment has applications in explaining deficits found in local and global function. Subjectively, patient reported outcome measures (PROMs) provide a measure of success from the patient's perspective, encompassing their expectations and subsequently their ability to function according to the demands of everyday life.

Global function

Motion capture of patients performing ADLs helps to establish a comprehensive understanding of post-operative function. From level-ground walking to higher demand activities such as squatting, information regarding the functional capacity of the hip joint to perform various tasks can be assessed. Gait is an important measure of function as it is the basic level of mobility required to preserve patient independence in everyday life, therefore establishing the functional impacts of the surgical approaches on gait for patients can help to account for and improve patient quality of life. Higher demand ADLs can accentuate the consequence of functional deficits and help to more clearly identify functional differences between surgical approaches¹⁴.

The direct lateral approach has been regularly linked to post-operative Trendelenburg gait in approximately 10% of cases when walking and climbing stairs¹⁵⁻¹⁸ without signs of improvement. This

Trendelenburg gait has been attributed to disruption of the abductor compartment (gluteus medius and minimus) during surgery^{11,12,19}. Compared to the anterolateral approach, the gait of people undergoing surgery using a direct lateral approach appears to differ more from control participants one year post-operatively in kinematic variables including hip ROM and pelvic asymmetry²⁰. Lasting abduction strength and ROM deficits are likely to impede patient quality of life by impeding mobility and ease of function.

A solitary study examining the effect of surgical approach on hip ROM demonstrated that those patients who underwent PA exhibited deficits in hip ROM compared to the DAA²¹. The external rotators play an important role in the maintenance of normal gait and abnormalities in strength or ROM can lead to pathological changes to gait²². Compensatory activation of gluteus maximus occurs secondarily to internal rotation of the hip in order to stabilise the joint²³. In the PA the gluteus maximus muscle is damaged, as well as tenotomisation of the external rotators, potentially resulting in reduced hip extension and external rotation which can cause gait abnormalities. When soft tissue repair and preservation of the joint capsule are practiced, patients return to near 'normal' gait values²⁴, alongside the benefits of reduced dislocation rates⁷. Rodriguez et al²⁵ tested patients' ability to perform the timed-up-and-go test. PA approach patients were slower than patients who underwent other approaches but this difference did not last beyond six weeks post-operatively. The PA does appear to cause gait deficits, particularly affecting extension and external rotation, yet these deficits appear to not persist in the long term and may potentially be modifiable by clinical intervention.

Despite the aforementioned findings, many studies assessing gait parameters have not reported significant differences between different surgical approaches, although variable post-operative improvements in gait have been noted for the various approaches in isolation²⁶⁻²⁹. Past studies examining the effect of THA surgical approach on gait have demonstrated significant deficits in hip ROM, peak hip abduction and gait velocity compared to control participants regardless of approach^{2,30,31}. Hip loading is also decreased in DAA THA, direct lateral and PA hip resurfacing patients,

all compared to control participants³² but there are no reports of differences between different surgical approaches. Identifying initial deficits in muscle groups may offer the opportunity for targeted post-operative physiotherapy in order to improve long-term functional outcomes. Subtle changes can remain in gait post-operatively²⁸; for example, reduced ground reaction forces in the operative limb³³, although it is not clear whether this may be due to behaviourally trained hesitancy persisting from pre-operative pathology rather than operative factors.

In summary, the gait of THA patients does not return to the levels of healthy controls after surgery. The direct lateral approach is associated with lasting abductor weakness whilst the posterior approach is associated with shorter term extension and rotation deficits. How long the differences persist following surgery employing these two approaches is currently unknown but functional disparity may be reactive to immediate or intensive treatment.

Take home message

- THA patients do not return to 'normal' gait when compared to healthy controls, regardless of approach
- Trendelenburg gait can be caused by the direct lateral approach
- External rotation and extension at the hip may be adversely affected by the posterior approach

Local function

Muscle strength plays an essential role in stabilising the joint and Muller suggests that the most important role of gluteus minimus is in the stabilisation of the femoral head. Preservation of this muscle is important therefore, to prevent dislocation and associated further difficulties³⁴. The superior gluteal nerve is also vulnerable to iatrogenic injury in the direct lateral approach^{35,36}; and damage can cause weakened abduction, which is already a known risk and which should be avoided. Loss of

function of the soft tissue structures that are required for hip stabilisation may have pathological consequences for the lower limb and for global function.

Evidence suggests that the anterolateral approach, a close relation to the direct lateral, results in reduced hip abduction and internal rotation strength compared to that following PA³⁷. Similarly, Lamontagne et al³⁸ demonstrated that the direct lateral approach leads to reduced abduction/adduction ROM compared to the DAA. In combination, these findings suggest that the direct lateral approach causes greater limitation of local function compared to the anterior approach. There is some evidence that contradicts the logical sequelae of the muscle damage in certain approaches. For example, Downing et al³⁹ found no difference in abductor strength or Trendelenburg test at 12 months post-surgery between PA and direct lateral patients. Despite the disruption of gluteus maximus, the main hip extensor, superior hip extensor strength has also been reported in PA cases compared to the DAA⁴⁰. Nonetheless, these findings are in relative isolation and counter the principle that disrupted muscle tissue is weakened, and therefore perhaps should be viewed with caution.

When the PA is used for hip resurfacing, disrupting the same muscle groups as when THA is performed (i.e. gluteus maximus and external rotators), evidence also suggests that hip strength and ROM are diminished and do not recover to pre-operative levels⁴¹. This adds weight to the expectation that patients who undergo THA through a posterior approach would also potentially exhibit diminished muscle function post-operatively.

The significance of soft tissue damage on muscle strength and ROM is not well understood, although it is clear that disruption of soft tissue reduces strength and is likely to have significant impact on global hip function i.e. walking and activities of daily living. Inability of the hip to function adequately can lead to overall lower limb deficits where the hip cannot work in a co-ordinated manner in relation to the other joints during movement. As a result, the potential for loss of ROM and strength of abduction in the direct lateral approach, and extension/external rotation limitation in the PA should be noted and

considered when operating. Furthermore, where muscle function is not restored sufficiently, targeted physiotherapy could be a solution as a means to restore strength and ROM⁴¹.

Take home message

- Hip abductor strength and frontal plane ROM are reduced in the direct lateral approach
- Hip external rotation strength and ROM is reduced in the posterior approach

Structure

Currently, the impact of muscle disruption on hip joint structures following direct lateral or PA THA is not sufficiently understood, due to a lack of studies employing soft tissue imaging around hip implants. The main obstacle to imaging has been metal artefact distortion associated with magnetic resonance imaging (MRI) around metal implants. New techniques in magnetic resonance imaging such as Slice Encoding for Metal Artefact Correction (SEMAC) allow correction of these distortions around the implant and provide clearer images of the implant and surrounding tissues. Imaging of structures and the associated outcome measures, such as muscle cross sectional area or fatty atrophy will potentially provide further evidence in future for understanding strength or global function deficits.

Take home message

- Identification of structural damage can explain deficits found in local and global function
- Emerging technologies (e.g. SEMAC, metal artefact reduction sequence (MARS)) should enable high quality imaging around the hip prosthesis and improved soft tissue assessment
- Imaging biomarkers such as cross sectional area and fatty atrophy can increasingly be used to understand the pathophysiology behind deficits

Perioperative Outcomes and Patients Reported Outcome Measures

Perioperative outcomes

Perioperative measures such as time to ambulation without walking aids and length of hospital stay are important in evaluating recovery of function. They provide a practical measure for clinicians to review outcomes that are relevant to the clinical environment and so enable simple post-operative monitoring of patient outcomes in the short-term. To our knowledge, perioperative evaluation has not been thoroughly assessed comparing posterior and lateral approaches directly, with current evidence limited to speculating on outcomes based on comparisons with less commonly performed approaches. The majority of past research has compared either the PA or direct lateral approach to the DAA but more direct comparisons are required to discover perioperative differences.

In a cost-analysis of 118 patients, Petis et al⁴² did not find any differences in hospital length of stay nor associated costs between the direct lateral and PAs. Faster recovery of function correlates with reduced length of stay and so can reduce the costs to hospitals. As previously mentioned, the posterior approach is associated with a risk of dislocation but this finding has not been compared specifically to the direct lateral approach⁶. Pain assessments, although a subjective measure, have also indicated that patients who undergo THA through a lateral approach experience more discomfort than those undergoing a DAA^{43,44}, narcotic analgesic use was also reported to be increased in patients who underwent PA compared with the DAA⁴⁵. There does not appear to be a significant difference between the PA and direct lateral approaches peri-operatively, however pain levels during recovery for both are slightly elevated compared to the DAA which is likely due to the relatively muscle-sparing approach of this latter technique.

Patient Reported Outcome Measures and Clinical Scores

Patient reported outcome measures (PROMs) are another subjective measure of the success of surgery; including scores based on local and general function such as the Oxford Hip Score (OHS). These measures are particularly important considering the older demographic of THA patients as they assess their functional ability to perform ADLs and therefore their independence, which is of importance to patients. Subjective outcome measures provide the patient perspective and reveal important information about the usability of the implanted hip in everyday life.

Christensen et al⁴⁶ demonstrated that only the magnitude of patient-reported pain suggested any significant disadvantage for the PA compared to DAA at 6 weeks postoperatively. Of the few studies comparing surgical approach on patient-reported hip function, the direct lateral and posterior THA Harris Hip Scores (HHS) and radiological measures were similar post-operatively⁴⁷. Similarly, a large study of 1089 patients did not find significant differences in OHS between anterolateral and PA THA at five year follow up⁴⁸. This is significant as the study considered medium-to-long term outcomes of THA and thus suggests that any early functional differences may dissipate beyond the short-term. A multi-centre study by Edmunds et al⁴⁹ found that PA patients had better HHS and fewer patients demonstrated Trendelenburg gait (2.2%) compared to anterolateral patients (5.7%) due to abductor disruption. Restrepo et al⁵⁰ found that up to two years post-surgery, lateral THA patients reported worse scores for mental health, physical condition and pain than DAA patients, using the validated Short-Form36 and Western Ontario McMaster Osteoarthritis Index. PROMs have indicated little difference in functional outcome between the PA and direct lateral approaches, partly because of a lack of direct comparison in studies. Both surgical approaches appear to exhibit worse recovery in the short term compared to muscle-sparing approaches.

Take home message

- There is little difference in functional outcome reported peri-operatively or by patients between the PA and direct lateral approaches
- Both approaches appear to have a slower recovery compared to the DAA, a muscle-sparing approach

CONCLUSIONS

Global function is affected by posterior and direct lateral approaches of THA, whilst deficits in gait are found for both approaches when compared with controls. This functional deficit is thought to remain post-operatively and there is currently no evidence to indicate that patients undergoing either approach patients recover fully to healthy control levels. Peri-operative recovery is largely similar for each approach, with differences limited to a potentially higher dislocation rate in the posterior approach.

Although they are variations on the same procedure, it is clear that the posterior and direct lateral approaches, due to their different paths of incision, have varying functional impacts. It has been established that the direct lateral approach is related to Trendelenburg gait in some patients, due to iatrogenic damage of the abductor compartment. Further evidence suggests that ROM in the frontal plane may also be reduced whilst there is thought to be a detrimental impact on muscle strength. The capacity of extension and external rotation at the hip are potentially sacrificed in the posterior approach due to its disruption of the gluteus maximus muscle. However, currently there is no consensus on whether the posterior, lateral or any other surgical approach is superior overall. The evidence as it stands currently, whilst unlikely to change surgeons' practice, provides useful information with which to understand the impact of the different surgical approaches on the THA patient. Ultimately consideration of these factors may inform post-operative rehabilitation regimens which can be tailored to each approach based on the anticipated functional compromises.

REFERENCES

1. Hamilton DF, Howie CR. Selecting the right hip replacement. *BMJ*. 2014;348.
2. Madsen MS, Ritter MA, Morris HH, et al. The effect of total hip arthroplasty surgical approach on gait. *Journal of orthopaedic research : official publication of the Orthopaedic Research Society*. 2004;22(1):44-50.

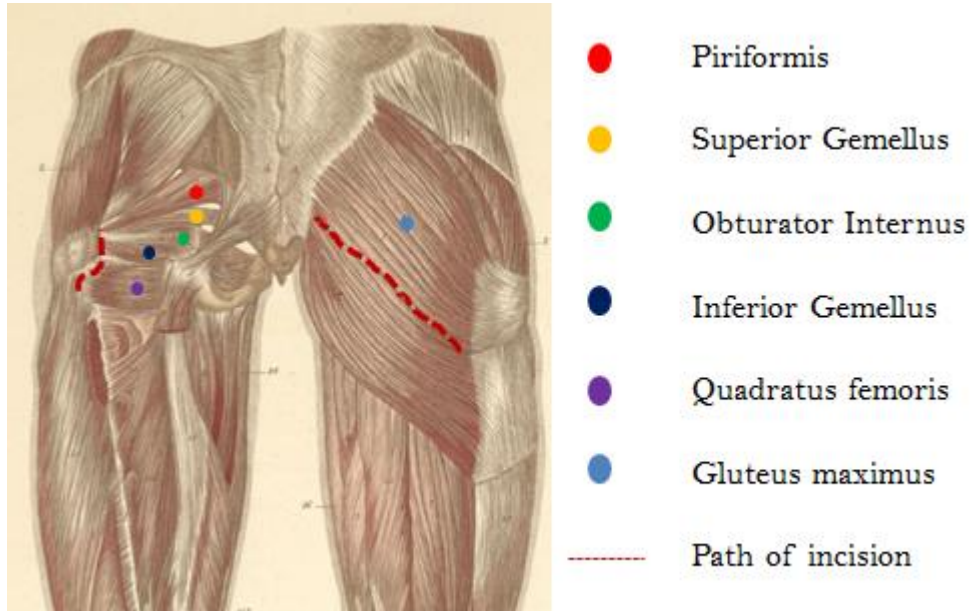
3. Registry NJ. *Characteristics of surgical practice for patients undergoing primary hip replacement*. National Joint Registry;2015.
4. Moore AT. The self-locking metal hip prosthesis. *J Bone Joint Surg Am*. 1957;39-a(4):811-827.
5. Berry DJ, Bozic KJ. Current practice patterns in primary hip and knee arthroplasty among members of the American Association of Hip and Knee Surgeons. *J Arthroplasty*. 2010;25(6 Suppl):2-4.
6. Tsukada S, Wakui M. Lower Dislocation Rate Following Total Hip Arthroplasty via Direct Anterior Approach than via Posterior Approach: Five-Year-Average Follow-Up Results. *Open Orthop J*. 2015;9:157-162.
7. Kwon MS, Kuskowski M, Mulhall KJ, Macaulay W, Brown TE, Saleh KJ. Does surgical approach affect total hip arthroplasty dislocation rates? *Clin Orthop Relat Res*. 2006;447:34-38.
8. Pellicci PM, Bostrom M, Poss R. Posterior approach to total hip replacement using enhanced posterior soft tissue repair. *Clin Orthop Relat Res*. 1998(355):224-228.
9. Barnsley L, Barnsley L, Page R. Are Hip Precautions Necessary Post Total Hip Arthroplasty? A Systematic Review. *Geriatric orthopaedic surgery & rehabilitation*. 2015;6(3):230-235.
10. Farrell CM, Springer BD, Haidukewych GJ, Morrey BF. Motor nerve palsy following primary total hip arthroplasty. *J Bone Joint Surg Am*. 2005;87(12):2619-2625.
11. Mulliken BD, Rorabeck CH, Bourne RB, Nayak N. A modified direct lateral approach in total hip arthroplasty: a comprehensive review. *J Arthroplasty*. 1998;13(7):737-747.
12. Demos HA, Rorabeck CH, Bourne RB, MacDonald SJ, McCalden RW. Instability in primary total hip arthroplasty with the direct lateral approach. *Clin Orthop Relat Res*. 2001(393):168-180.
13. Picado CH, Garcia FL, Marques W, Jr. Damage to the superior gluteal nerve after direct lateral approach to the hip. *Clin Orthop Relat Res*. 2007;455:209-211.
14. van den Akker-Scheek I, Stevens M, Bulstra SK, Groothoff JW, van Horn JR, Zijlstra W. Recovery of gait after short-stay total hip arthroplasty. *Archives of physical medicine and rehabilitation*. 2007;88(3):361-367.
15. Baker AS, Bitounis VC. Abductor function after total hip replacement. An electromyographic and clinical review. *J Bone Joint Surg Br*. 1989;71(1):47-50.
16. Masonis JL, Bourne RB. Surgical approach, abductor function, and total hip arthroplasty dislocation. *Clin Orthop Relat Res*. 2002(405):46-53.
17. Lamontagne M, Beaulieu ML, Beaulieu PE. Comparison of joint mechanics of both lower limbs of THA patients with healthy participants during stair ascent and descent. *Journal of orthopaedic research : official publication of the Orthopaedic Research Society*. 2011;29(3):305-311.
18. Beaulieu ML, Lamontagne M, Beaulieu PE. Lower limb biomechanics during gait do not return to normal following total hip arthroplasty. *Gait & posture*. 2010;32(2):269-273.
19. Johnston RC, Fitzgerald RH, Jr., Harris WH, Poss R, Muller ME, Sledge CB. Clinical and radiographic evaluation of total hip replacement. A standard system of terminology for reporting results. *J Bone Joint Surg Am*. 1990;72(2):161-168.
20. Kiss RM, rp, Illy d. Comparison of gait parameters in patients with total hip arthroplasty following direct lateral and anterolateral surgical approach. Proceedings of the Sixth IASTED International Conference on Biomedical Engineering; 2008; Innsbruck, Austria.
21. Rathod PA, Orishimo KF, Kremenich IJ, Deshmukh AJ, Rodriguez JA. Similar improvement in gait parameters following direct anterior & posterior approach total hip arthroplasty. *J Arthroplasty*. 2014;29(6):1261-1264.
22. Ninos J. A Chain Reaction: The Hip Rotators. *Strength & Conditioning Journal*. 2001;23(2):26-27.
23. Souza RB, Powers CM. Differences in hip kinematics, muscle strength, and muscle activation between subjects with and without patellofemoral pain. *The Journal of orthopaedic and sports physical therapy*. 2009;39(1):12-19.

24. Holnapy G, Illyes A, Kiss RM. Impact of the method of exposure in total hip arthroplasty on the variability of gait in the first 6 months of the postoperative period. *Journal of electromyography and kinesiology : official journal of the International Society of Electrophysiological Kinesiology*. 2013;23(4):966-976.
25. Rodriguez JA, Deshmukh AJ, Rathod PA, et al. Does the Direct Anterior Approach in THA Offer Faster Rehabilitation and Comparable Safety to the Posterior Approach? *Clin Orthop Relat Res*. 2014;472(2):455-463.
26. Meneghini RM, Smits SA, Swinford RR, Bahamonde RE. A randomized, prospective study of 3 minimally invasive surgical approaches in total hip arthroplasty: comprehensive gait analysis. *J Arthroplasty*. 2008;23(6 Suppl 1):68-73.
27. Queen RM, Butler RJ, Watters TS, Kelley SS, Attarian DE, Bolognesi MP. The effect of total hip arthroplasty surgical approach on postoperative gait mechanics. *J Arthroplasty*. 2011;26(6 Suppl):66-71.
28. Queen RM, Appleton JS, Butler RJ, et al. Total hip arthroplasty surgical approach does not alter postoperative gait mechanics one year after surgery. *Pm r*. 2014;6(3):221-226; quiz 226.
29. Maffiuletti NA, Impellizzeri FM, Widler K, et al. Spatiotemporal parameters of gait after total hip replacement: anterior versus posterior approach. *Orthop Clin North Am*. 2009;40(3):407-415.
30. Varin D, Lamontagne M, Beaulé PE. Does the anterior approach for THA provide closer-to-normal lower-limb motion? *J Arthroplasty*. 2013;28(8):1401-1407.
31. Reininga IH, Stevens M, Wagenmakers R, et al. Comparison of gait in patients following a computer-navigated minimally invasive anterior approach and a conventional posterolateral approach for total hip arthroplasty: a randomized controlled trial. *Journal of orthopaedic research : official publication of the Orthopaedic Research Society*. 2013;31(2):288-294.
32. Wesseling M, Meyer C, Corten K, Simon J-P, Desloovere K, Jonkers I. Does surgical approach or prosthesis type affect hip joint loading one year after surgery? *Gait & posture*. 2016;44:74-82.
33. McCrory JL, White SC, Lifeso RM. Vertical ground reaction forces: objective measures of gait following hip arthroplasty. *Gait & posture*. 2001;14(2):104-109.
34. Muller M, Tohtz S, Winkler T, Dewey M, Springer I, Perka C. MRI findings of gluteus minimus muscle damage in primary total hip arthroplasty and the influence on clinical outcome. *Arch Orthop Trauma Surg*. 2010;130(7):927-935.
35. Bertin KC, Rottinger H. Anterolateral mini-incision hip replacement surgery: a modified Watson-Jones approach. *Clin Orthop Relat Res*. 2004(429):248-255.
36. Barrack RL. Neurovascular injury: avoiding catastrophe. *J Arthroplasty*. 2004;19(4 Suppl 1):104-107.
37. Gore DR, Murray MP, Sepic SB, Gardner GM. Anterolateral compared to posterior approach in total hip arthroplasty: differences in component positioning, hip strength, and hip motion. *Clin Orthop Relat Res*. 1982(165):180-187.
38. Lamontagne M, Varin D, Beaulé PE. Does the anterior approach for total hip arthroplasty better restore stair climbing gait mechanics? *Journal of orthopaedic research : official publication of the Orthopaedic Research Society*. 2011;29(9):1412-1417.
39. Downing ND, Clark DI, Hutchinson JW, Colclough K, Howard PW. Hip abductor strength following total hip arthroplasty: a prospective comparison of the posterior and lateral approach in 100 patients. *Acta orthopaedica Scandinavica*. 2001;72(3):215-220.
40. Krych AJ, Pagnano MW, Wood KC, Meneghini RM, Kaufmann K. No Benefit of the Two-incision THA over Mini-posterior THA: A Pilot Study of Strength and Gait. *Clin Orthop Relat Res*. 2010;468(2):565-570.
41. Hakkinen A, Borg H, Kautiainen H, et al. Muscle strength and range of movement deficits 1 year after hip resurfacing surgery using posterior approach. *Disabil Rehabil*. 2010;32(6):483-491.

42. Petis SM, Howard JL, Lanting BA, Marsh JD, Vasarhelyi EM. In-Hospital Cost Analysis of Total Hip Arthroplasty: Does Surgical Approach Matter? *J Arthroplasty*. 2015.
43. Alecci V, Valente M, Crucil M, Minerva M, Pellegrino CM, Sabbadini DD. Comparison of primary total hip replacements performed with a direct anterior approach versus the standard lateral approach: perioperative findings. *Journal of orthopaedics and traumatology : official journal of the Italian Society of Orthopaedics and Traumatology*. 2011;12(3):123-129.
44. Dienstknecht T, Luring C, Tingart M, Grifka J, Sendtner E. Total hip arthroplasty through the mini-incision (Micro-hip) approach versus the standard transgluteal (Bauer) approach: a prospective, randomised study. *Journal of orthopaedic surgery (Hong Kong)*. 2014;22(2):168-172.
45. Zawadsky MW, Paulus MC, Murray PJ, Johansen MA. Early outcome comparison between the direct anterior approach and the mini-incision posterior approach for primary total hip arthroplasty: 150 consecutive cases. *J Arthroplasty*. 2014;29(6):1256-1260.
46. Christensen CP, Jacobs CA. Comparison of Patient Function during the First Six Weeks after Direct Anterior or Posterior Total Hip Arthroplasty (THA): A Randomized Study. *J Arthroplasty*. 2015;30(9 Suppl):94-97.
47. Barber TC, Roger DJ, Goodman SB, Schurman DJ. Early outcome of total hip arthroplasty using the direct lateral vs the posterior surgical approach. *Orthopedics*. 1996;19(10):873-875.
48. Palan J, Beard DJ, Murray DW, Andrew JG, Nolan J. Which approach for total hip arthroplasty: anterolateral or posterior? *Clin Orthop Relat Res*. 2009;467(2):473-477.
49. Edmunds CT, Boscainos PJ. Effect of surgical approach for total hip replacement on hip function using Harris Hip scores and Trendelenburg's test. A retrospective analysis. *The surgeon : journal of the Royal Colleges of Surgeons of Edinburgh and Ireland*. 2011;9(3):124-129.
50. Restrepo C, Parvizi J, Pour AE, Hozack WJ. Prospective randomized study of two surgical approaches for total hip arthroplasty. *J Arthroplasty*. 2010;25(5):671-679.e671.

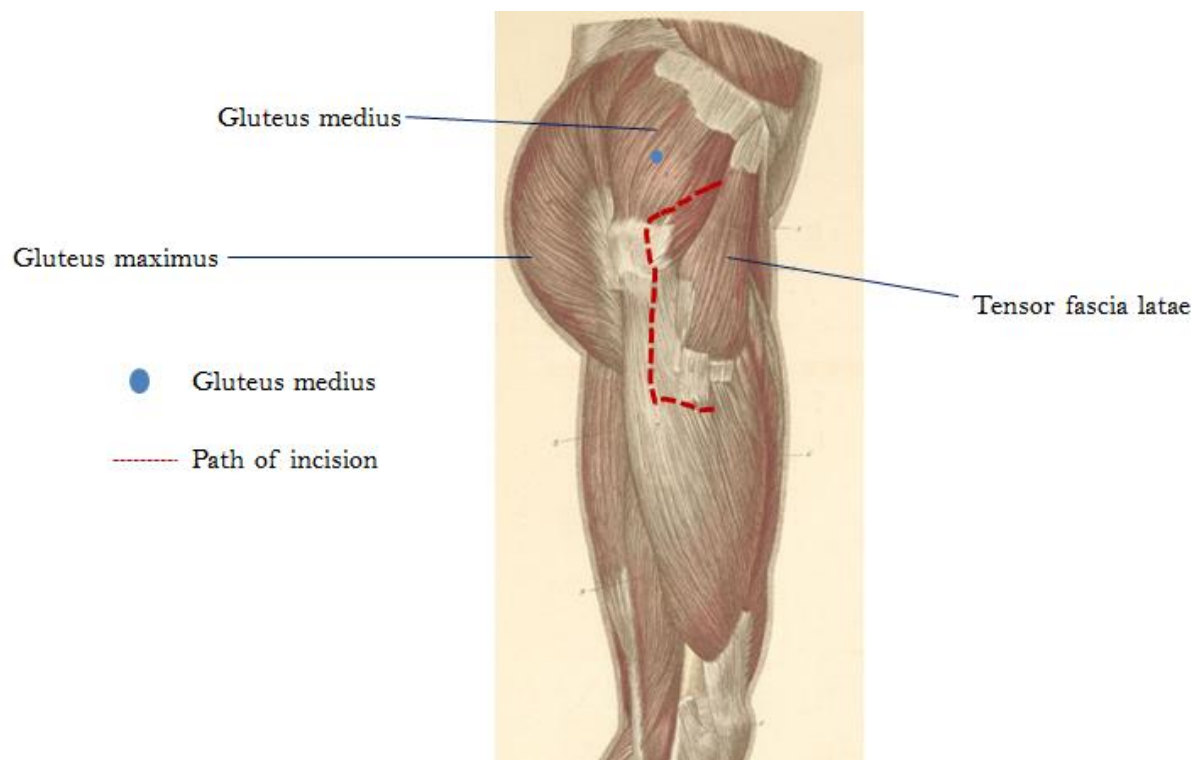
FIGURES

Figure 1. Anatomy of the muscles disrupted in posterior approach THA



Gluteus maximus muscle (blue circle) is split in line with the muscle fibres in order to minimise muscle trauma as much as possible as indicated by the red dotted line. The external rotators highlighted by the circles (superiorly to inferiorly); piriformis (red), superior gemellus (yellow), obturator internus (green), inferior gemellus (navy), quadratus femoris (purple). *Figure adapted from Atlas of Anatomy, Ernest et al (1841)*

Figure 2. Anatomy of the muscles disrupted in direct lateral THA



The red dashed line indicates the path of the M-shaped incision in the gluteus medius and part of vastus lateralis (blue circle). *Figure adapted from Atlas of Anatomy, Ernest et al (1841)*